

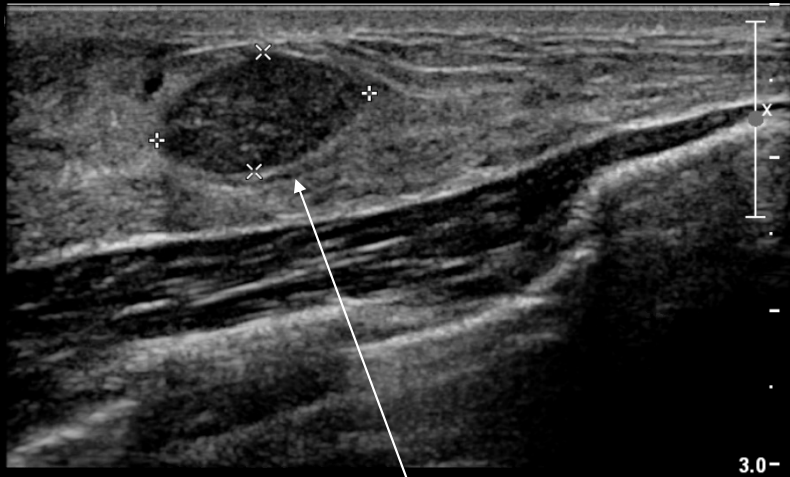
Fibroadenoma

Case

- 24 year old female presents to her PCP due to a mass in her right breast
- She has no medical history
- Family history is significant for a grandma with breast cancer diagnosed at age 70
- Physical exam shows a painless, firm, circumscribed nodule that is mobile. No nipple discharge.

DDx for breast mass

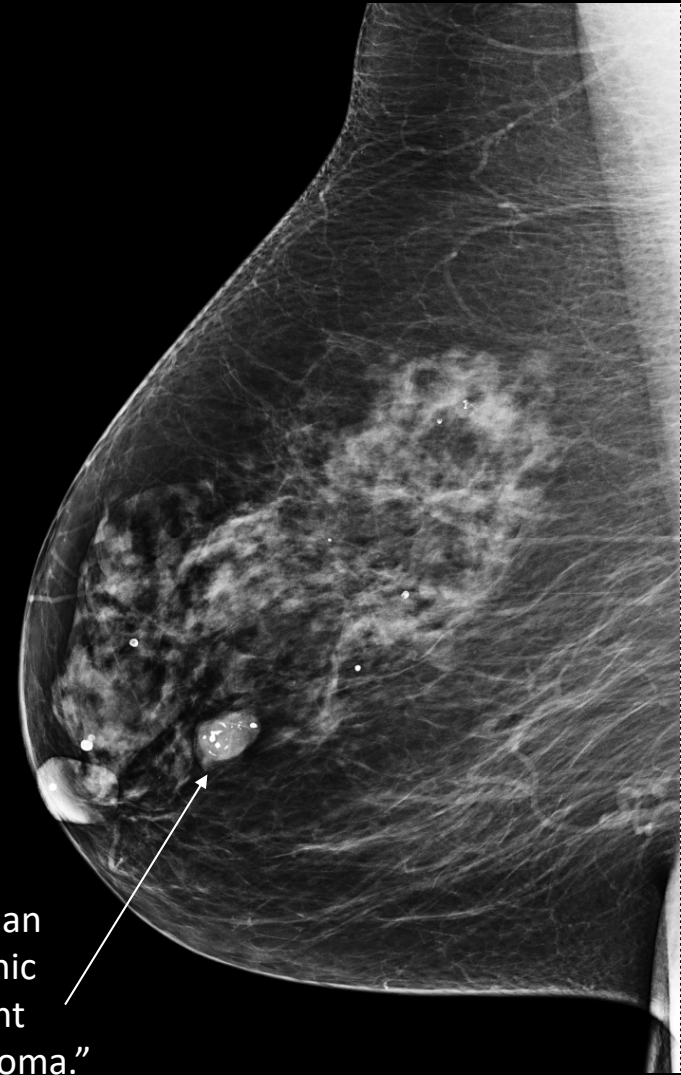
- Fibroadenoma
- Cyst
- Fat necrosis
- Fibrocystic change
- Phyllodes tumor
- Breast cancer



ULTRASOUND

“Ultrasound of the breast demonstrates a solid hypoechoic circumscribed mass. The appearance is most compatible with a fibroadenoma.”

RMLO



MAMMOGRAM

“Within the right breast, there is an oval isodense mass with dystrophic peripheral calcifications consistent with benign involuting fibroadenoma.”

About fibroadenomas

- Classic boards presentation is a smooth, mobile, rubbery, nontender mass in a young woman
- Stimulated by estrogen and progesterone so they may grow in pregnancy and shrink during menopause
- US is best imaging tool for young women
- Management: follow up every 6 months for 2 years to prove stability
 - May be surgically removed if large or by patient preference
 - If it grows >20% in 6 months, it should be biopsied!