Lab 10 – Nervous Tissue

IUSM – 2016

Nervous Tissue

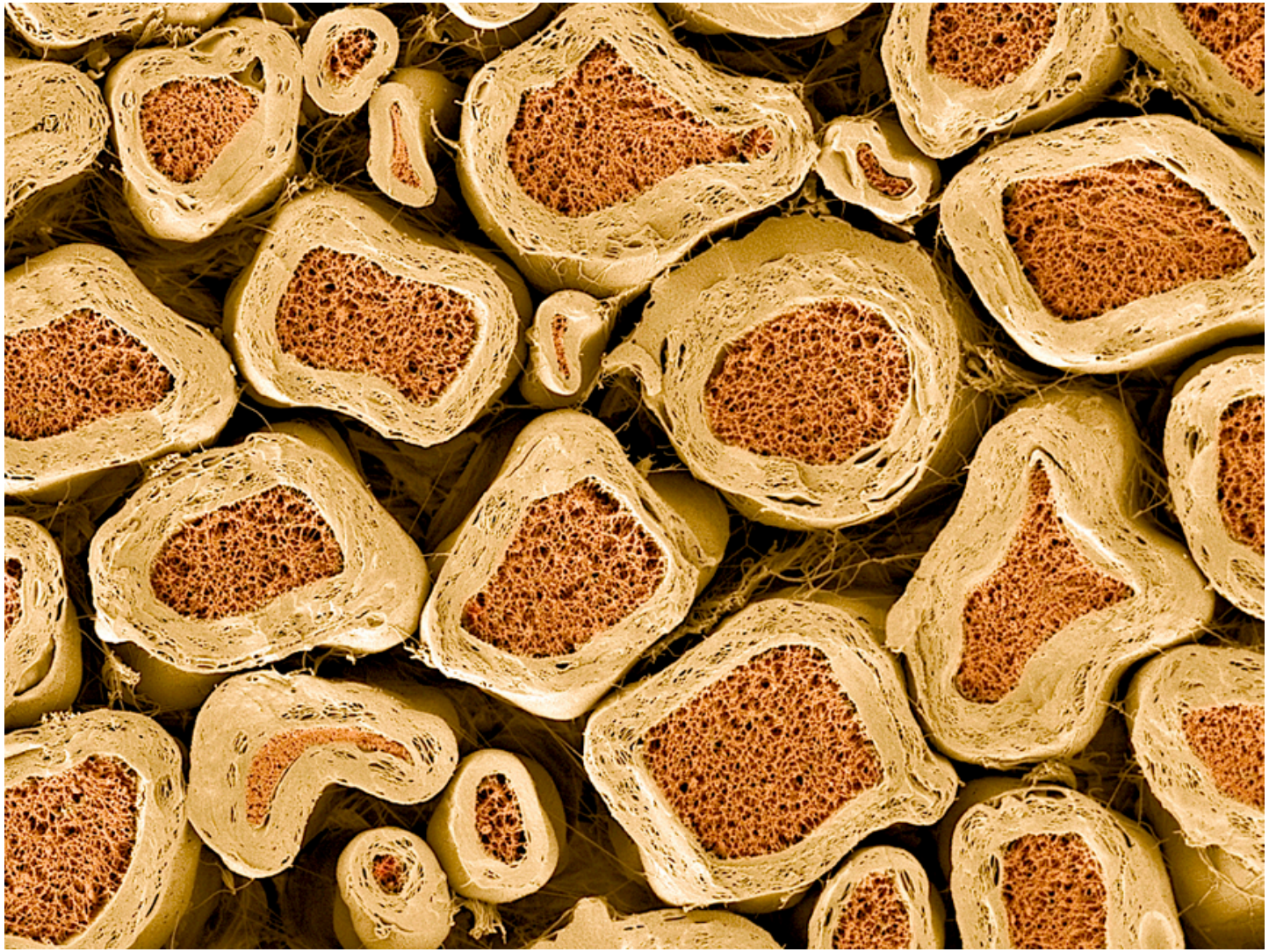

SEM of myelinated axons in a peripheral nerve.

Lab 10 – Nervous Tissue

IUSM – 2016

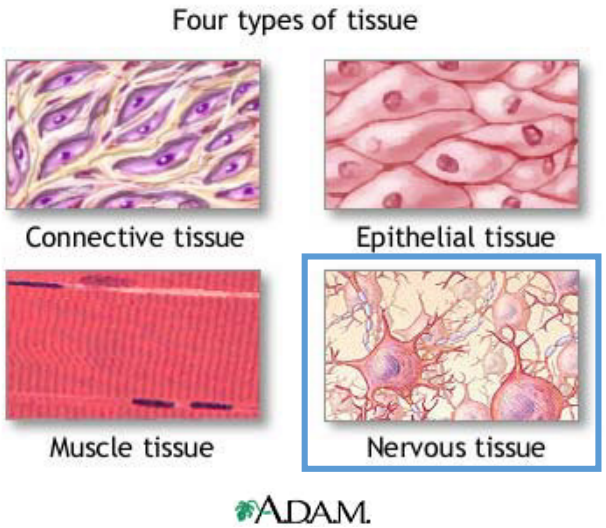

Nervous Tissue

1. Nervous tissue integrates and coordinates the activities of the body's cells and organs through conduction of electrical impulses and secretion of chemical neurotransmitters.

2. Nervous tissue consists of two main types of cells: **neurons** which are the functional cells of the nervous system and specialized to receive stimuli and transmit electrical impulses, and support cells (**neuroglia**), which do not conduct impulses but serve to support neuron function.

3. The nervous system is *anatomically divided* into the **central nervous system** (brain and spinal cord) and the **peripheral nervous system** (ganglia, nerves, and sensory receptors).

4. The nervous system is *functionally divided* into the **somatic nervous system** (under conscious control, except reflex arcs) and **autonomic nervous system** (involuntary control), which is further divided into the **sympathetic** and **parasympathetic** (and **enteric**) divisions.

Learning Objectives

1. Understand that nervous tissues contain both neurons and supporting cells (neuroglial cells).

2. Understand the nature of neuronal cell bodies, axons, and dendrites and their functional significance.

3. Understand that materials move in axons through retrograde and anterograde transport and the importance of this movement for axons growth/regeneration.

4. Understand the different types of neurons based on structure and connectivity: bipolar, unipolar, and multipolar.

5. Know the connective tissue coverings in peripheral nerves and their roles.

6. Understand the structure and function of myelin sheaths of axons in the CNS and PNS, how myelin is produced and maintained, and the difference between myelinated and unmyelinated fibers in peripheral nerves.

7. Understand the major features of synapses.

Learning Objectives (cont.)

8. Understand the histological structure of peripheral ganglia.

9. Understand the roles of endothelial cells and astrocytes in the blood-brain barrier.

10. Understand the interrelationship among ependymal cells, choroid plexus, and cerebrospinal fluid (CSF) production.

11. Understand the structure and functions of the meninges and their relationship to nervous tissue of the CNS.

Lab 10 – Nervous Tissue

IUSM – 2016

Keywords

Arachnoid mater
Astrocyte
Autonomic ganglia
Central canal
Central nervous system
Cerebellum
Cerebral cortex
Choroid plexus
Dorsal root ganglion
Dura mater
Endoneurium
Ependymal cells
Epineurium
Granular layer
Grey matter
Molecular layer
Motor end plate
Myelinated fiber
Neuron
Neuropil
Nissl substance
Nodes of Ranvier
Oligodendrocyte
Perineurium
Peripheral nerve
Pia mater
Purkinje cell
Satellite cells
Schwann cell
Synaptic vesicles
Terminal bouton
White matter

Slide 125: Cerebrum, H&E

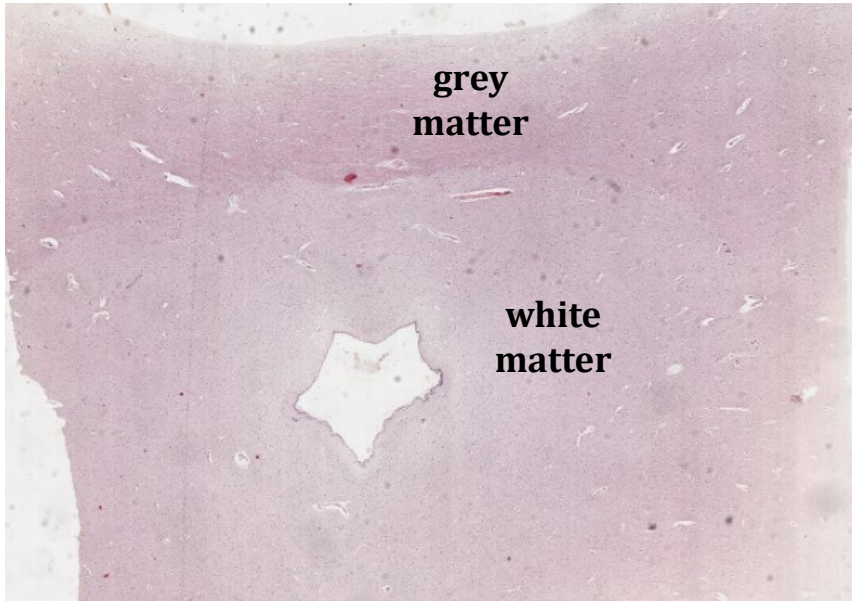

Slide 9: Spinal Cord, H&E

the **central nervous system** (CNS) consists of the **brain** (**cerebrum** and **cerebellum**) and **spinal cord**; when unstained, the tissue of the CNS is classified as grey matter and white matter based upon appearance: the **grey matter** contains the cell bodies of neurons and associated supportive neuroglial cells, while the **white matter** lacks neuron cell bodies and consists primarily of myelinated axons which give the 'whitish' coloration

in the spinal cord, the grey matter is located in the center and is surrounded by white matter on the outside; however, the orientation is opposite in the cerebellum and cerebral cortex (outer portion of the cerebrum) where the grey matter is located on the outside and surrounds the inner white matter; the "transition" between the two orientations occurs in the intervening connecting regions of the brainstem, thalamus, and basal ganglia

Slide 112: Cerebrum, H&E

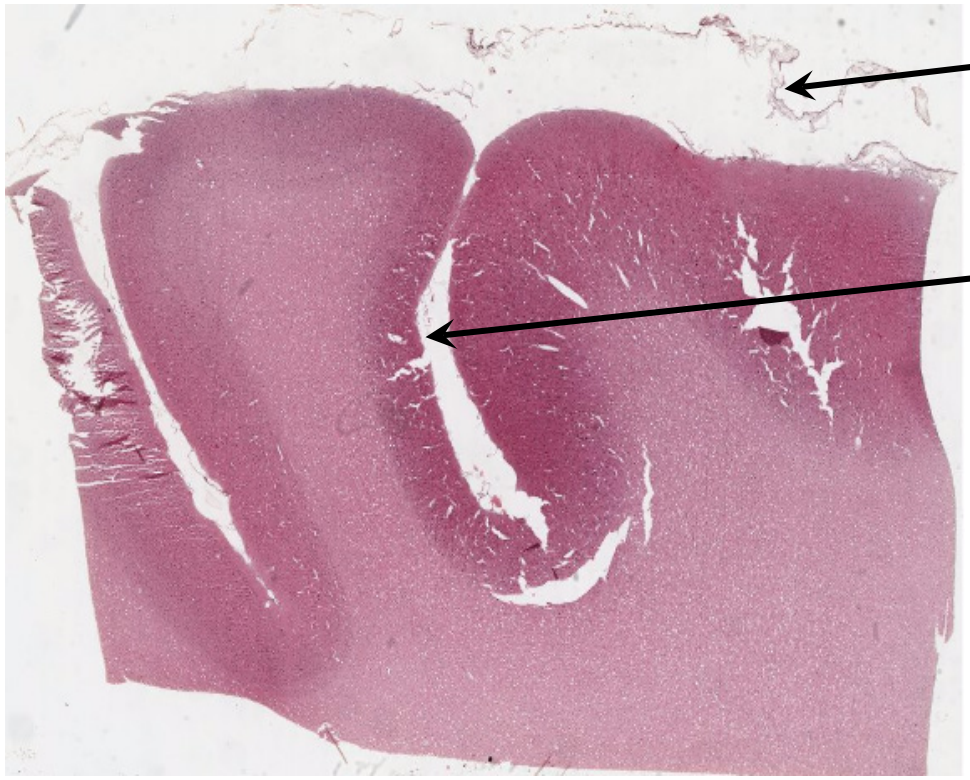

look here for **arachnoid**

look here for **pia mater**

the arachnoid and pia are normally highly interconnected by trabeculae and often are referred to collectively as the pia-arachnoid or leptomeninges

connective tissue is absent from the interior of the CNS, but three layers of CT cover the CNS surface (both the brain and spinal cord); these layers of CT are called the **meninges** (Gr. "membrane"), and from outermost to innermost are: **dura mater** (Lt. "tough mother"), **arachnoid** (Lt. "spider web-like"), and **pia mater** (Lt. "tender mother")

dura mater is rarely seen on slides of the brain, as it generally remains attached to the skull when removing the brain; occasionally on slides the **arachnoid** can be seen as a layer of dense CT above the *subarachnoid space* (normally contains CSF) and spanning the *sulci* ("grooves" of the cerebral cortex); the **pia mater** is located directly on the CNS surface so can be seen lining the *sulci*

Slide 112: Cerebrum, H&E

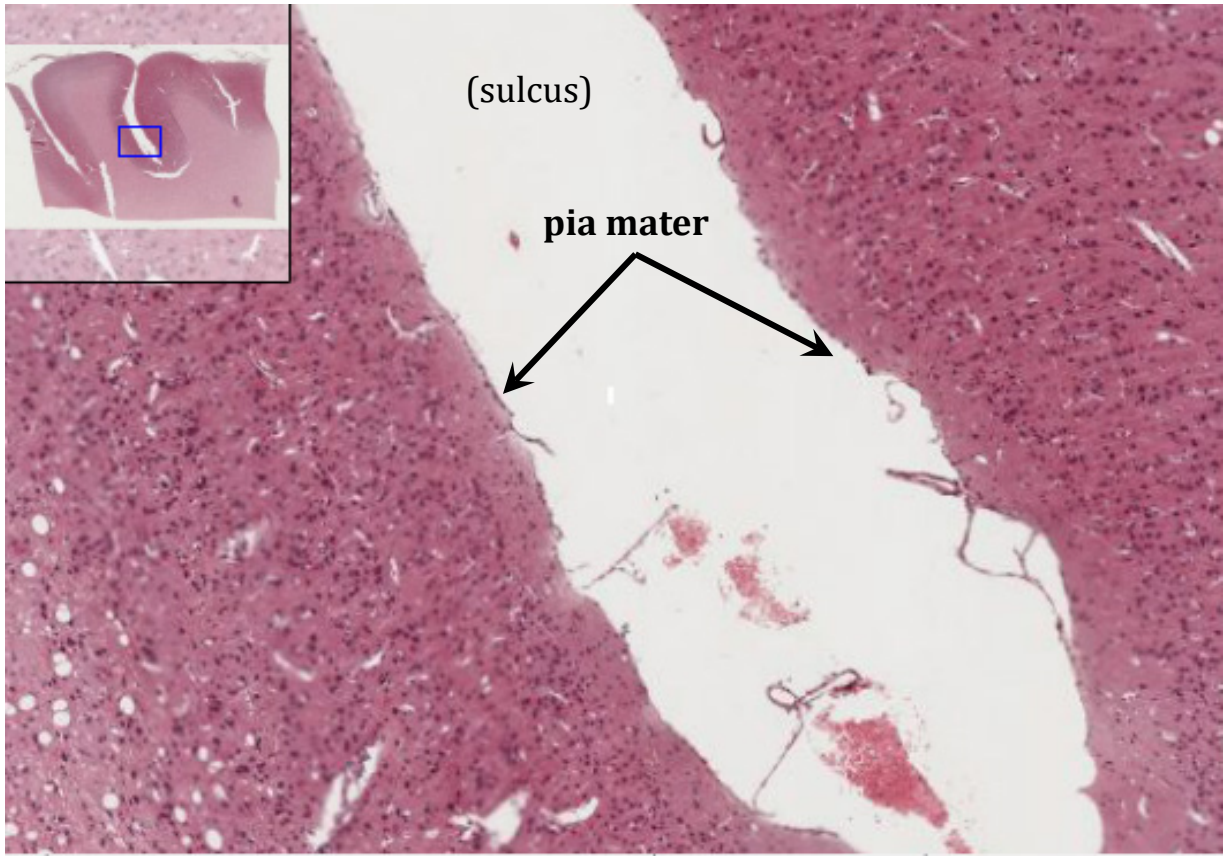

pia mater is a delicate layer consisting of flattened, impermeable cells and CT fibers; it rests upon a limiting layer of astrocyte foot processes known as the *glial limitans* (not seen in routine slide preparations) which acts as a barrier between the CNS neural tissue and surrounding non-neural tissue; as blood vessels penetrate into the CNS, they are initially surrounded by pia mater and the *glial limitans*, but as the vessels branch into smaller capillaries, the pia mater is no longer present, leaving only the *glial limitans* which surrounds the endothelial cells of the capillaries and facilitates formation of the *blood-brain barrier*

Slide 125: Cerebrum, H&E

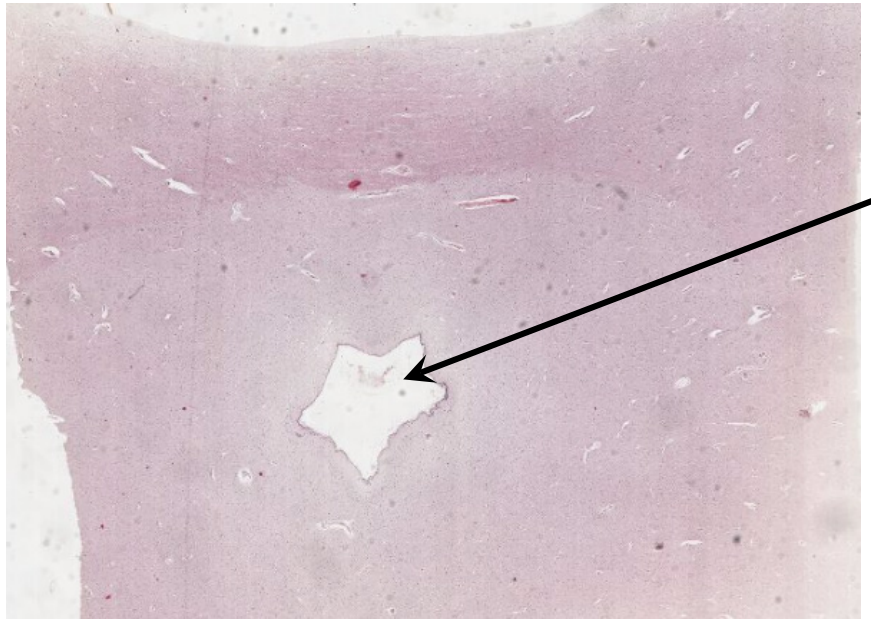

the *ventricles* (lateral, third, and fourth) are a continuous network of fluid-filled cavities within the brain where cerebrospinal fluid (CSF) is produced by **choroid plexuses**; CSF circulates from the ventricles into the *subarachnoid space* where it provides cushioning for the CNS and is ultimately reabsorbed into the venous blood

the *ventricles* are lined by **ependymal cells**, a type of neuroglial cell; they are epithelial-like cells generally simple cuboidal or columnar in shape; however, they are not an epithelium as they lack a true basement membrane

Slide 71: Cerebellum, Cresyl Violet

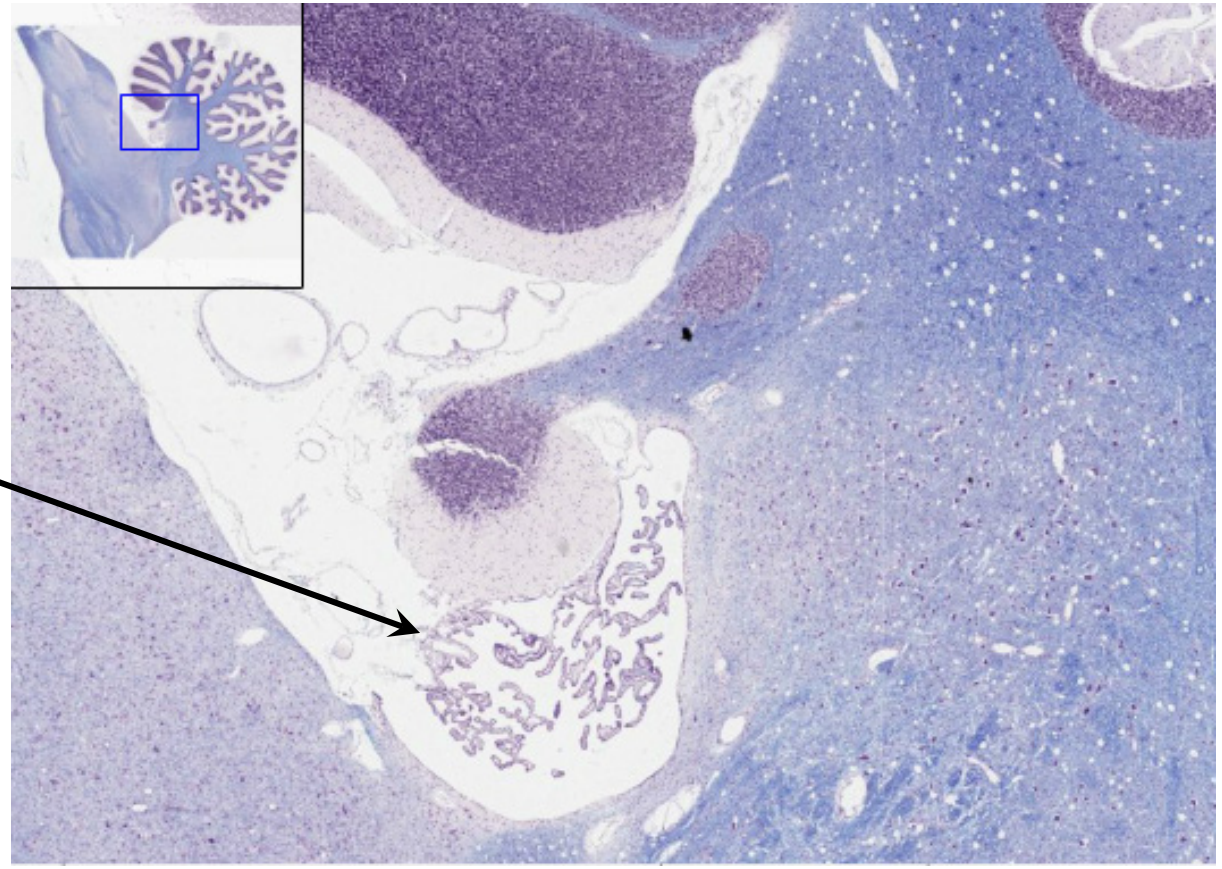

look in the ventricle (fourth) near the cerebellum to see the **choroid plexus**

Slide 71: Cerebellum, Cresyl Violet

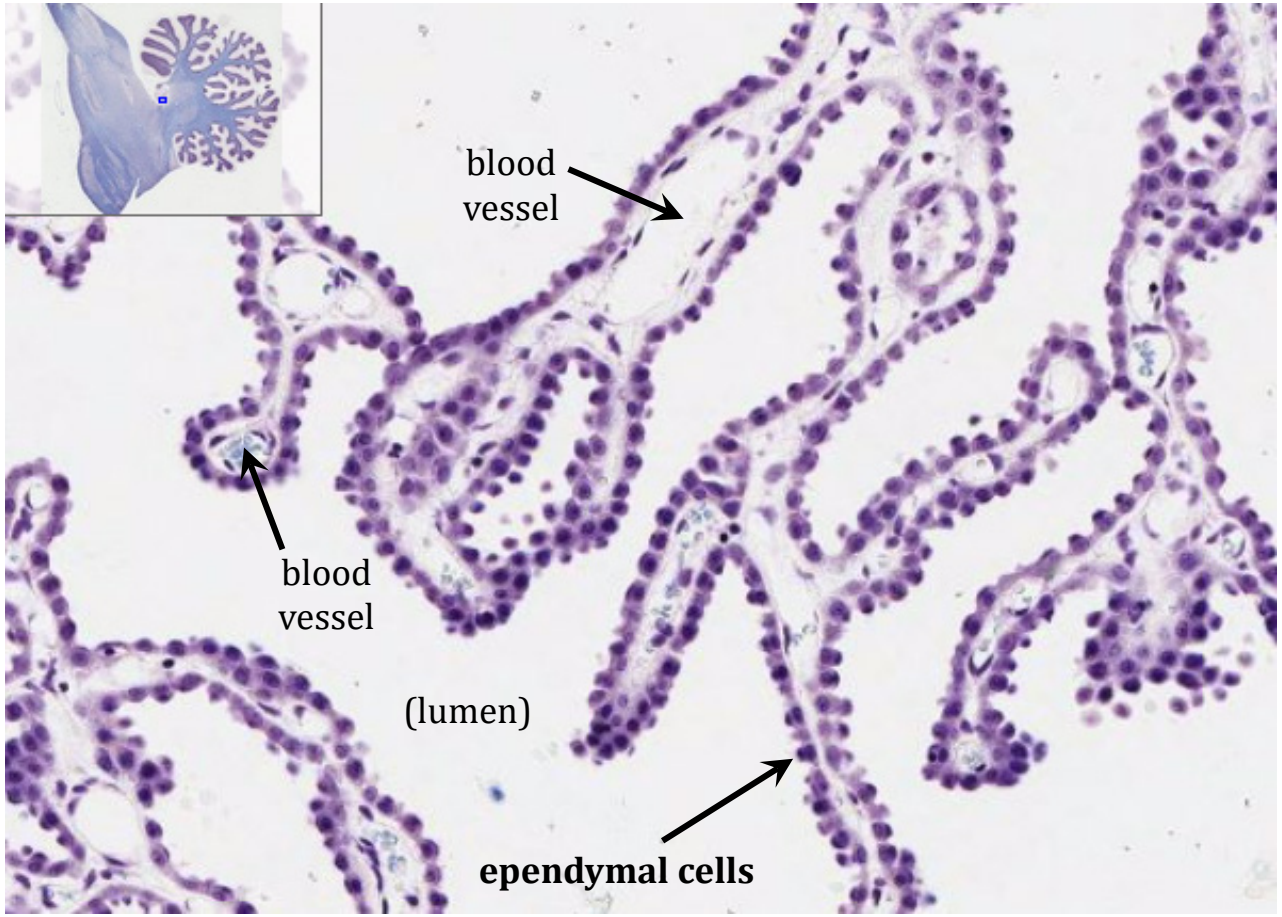

a **choroid plexus** is found in each of the four ventricles of the brain and is composed of cuboidal **ependymal cells** (type of neuroglial cell) and well-vascularized **pia mater**; the choroid plexus transports ions and water from the blood into the ventricles, creating cerebrospinal fluid (CSF)

Lab 10 – Nervous Tissue

IUSM – 2016

Slide 112: Cerebrum, H&E

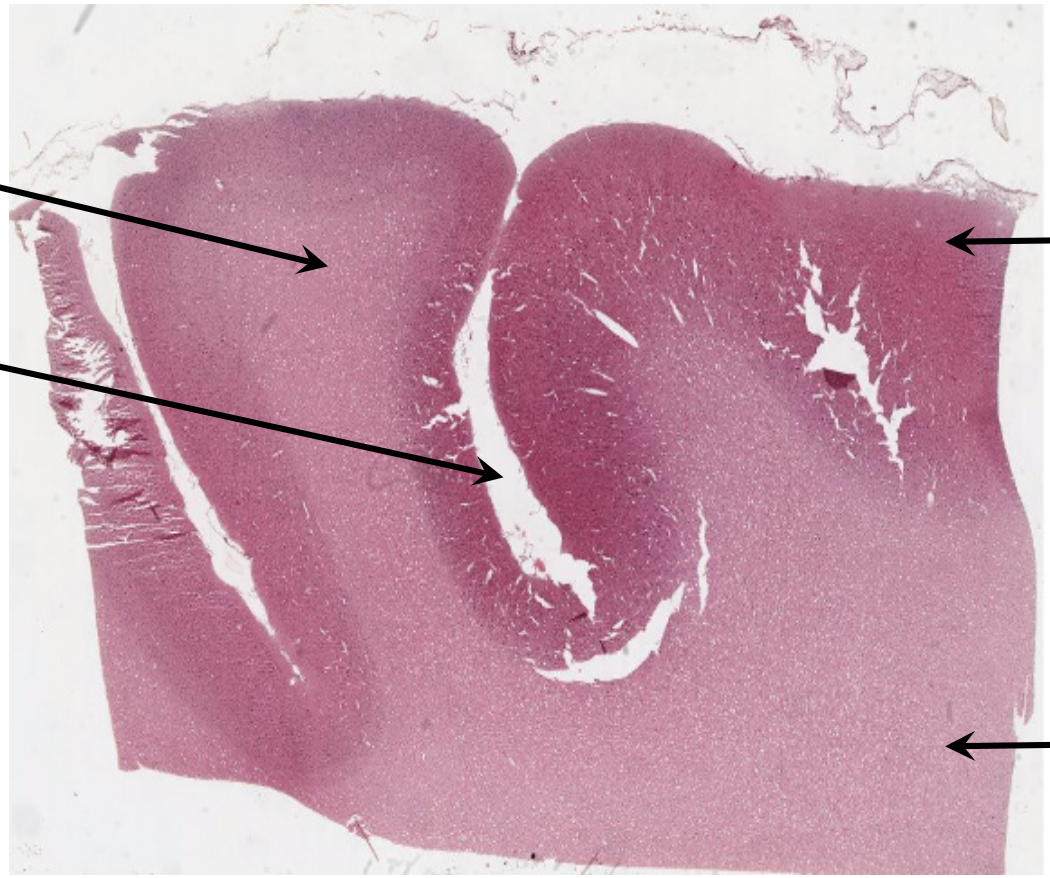

gyrus (bulge)

sulcus (groove)

look here at **cerebral cortex** for **grey matter**

look here for **white matter**

Slide 112: Cerebrum, H&E

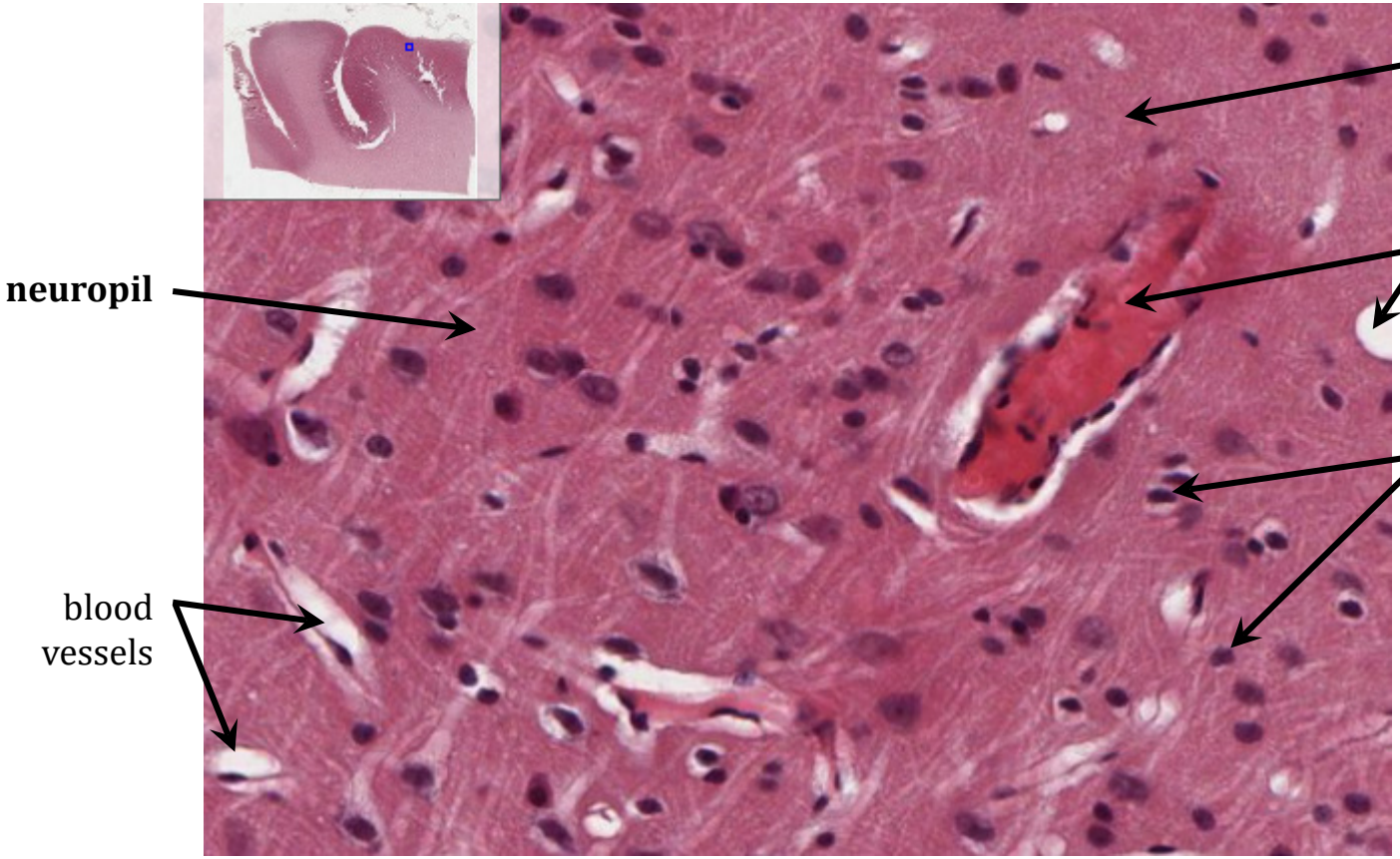

in grey matter, **neuropil** is the region (the "stuff") between cell bodies containing a dense meshwork of cellular processes (unmyelinated axons, dendrites, and neuroglial cell process); it is not connective tissue and its fine organization is not generally discernable in routine slide preparations

Slide 112: Cerebrum, H&E

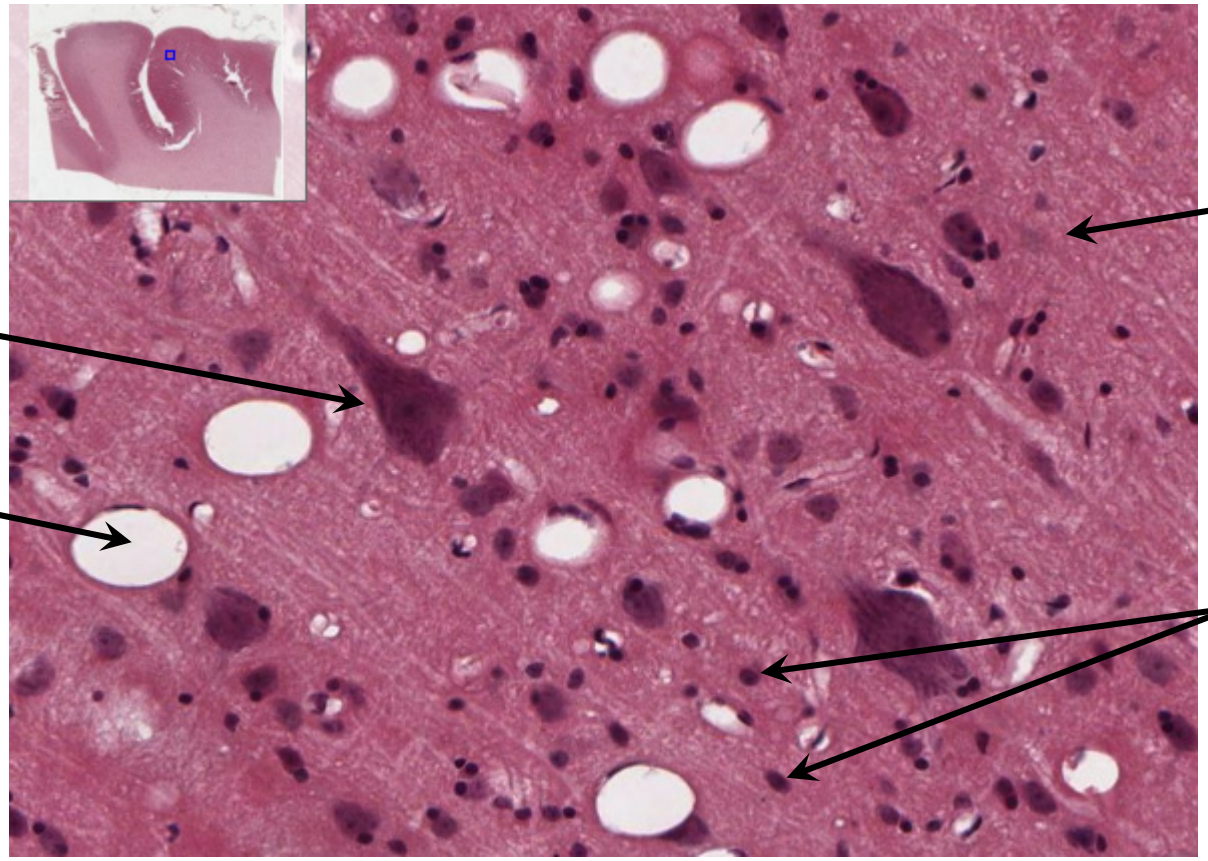

neurons are generally considered the "functional" cells of nervous tissue as they – unlike neuroglial cells – are capable of impulse conduction and synthesis of neurotransmitters; they can vary greatly in size and shape based upon location and function (e.g., sensory, motor, or interneuron); however, they usually appear much larger than surrounding neuroglial cells and have a well-defined nucleus with Nissl substance (rER) in the cytoplasm

Slide 112: Cerebrum, H&E

identifying specific types of neuroglial cells in standard H&E slides can be challenging: **oligodendrocytes**, which each may be associated with 50 or more neurons, are responsible for producing myelin in the CNS by wrapping processes (lipid sheaths) around neurons and their axons; they generally have "halos" of poorly-stained cytoplasm due to abundant Golgi complexes; **astrocytes** are the most abundant neuroglial cells of grey matter; they generally appear larger than oligodendrocytes and may be distinguished by not being directly associated with neurons and by having more darkly-stained cytoplasm

Slide 112: Cerebrum, H&E

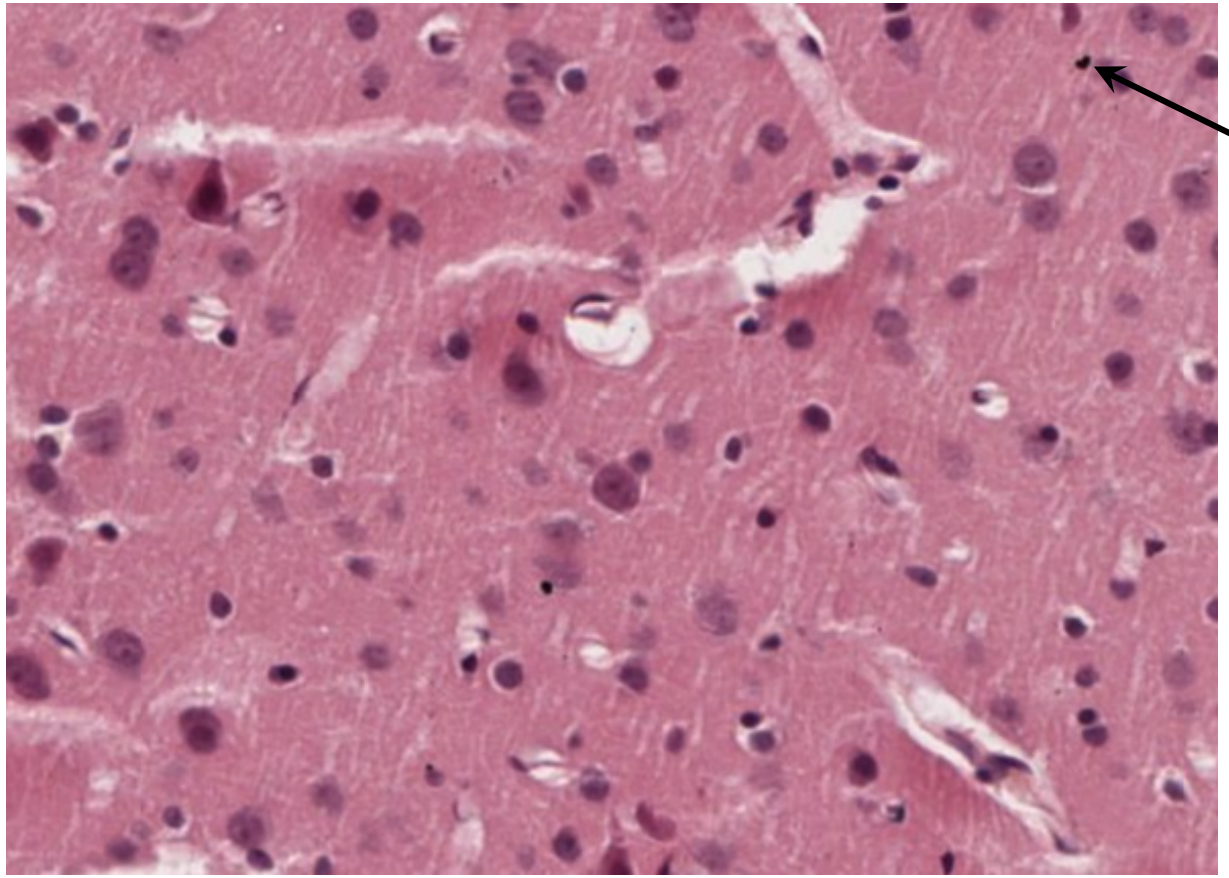

microglial (?) cells are difficult to identify with a high degree of certainty in routine slide preparations; they are small cells with little cytoplasm and a dense, elongated nucleus, often resembling a fibroblast

microglia are mobile phagocytic cells of neural tissue; they are the resident immune cells of the CNS, which otherwise is limited in mounting immune responses due to the restrictiveness of the blood-brain barrier; microglia are the smallest and least numerous of the neuroglial cells, but upon stimulation the cells can proliferate and change morphology

Slide 112: Cerebrum, H&E

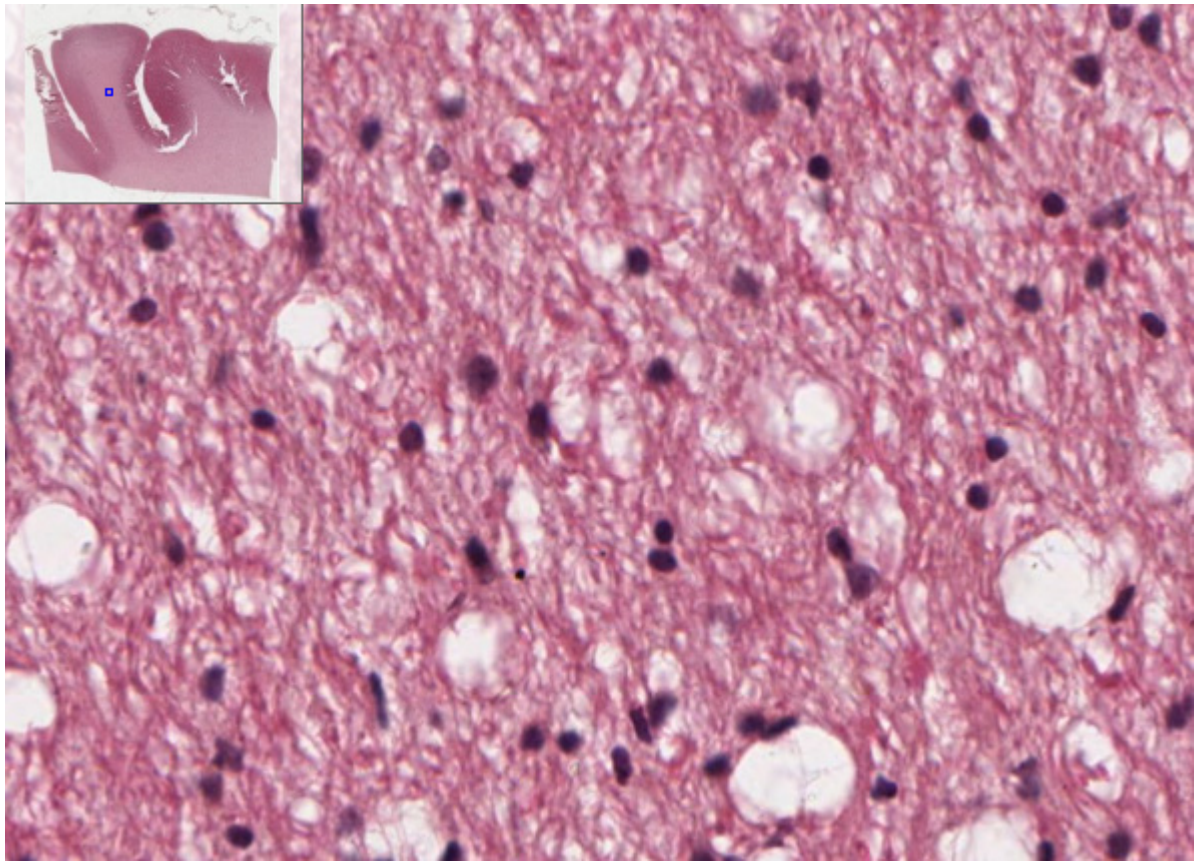

white matter is located deep to the grey matter of the cerebral cortex; it lacks neuron cell bodies and primarily contains myelinated axons and supportive neuroglial cells, mainly the oligodendrocytes that myelinate the axons

Slide 71: Cerebellum, Cresyl Violet

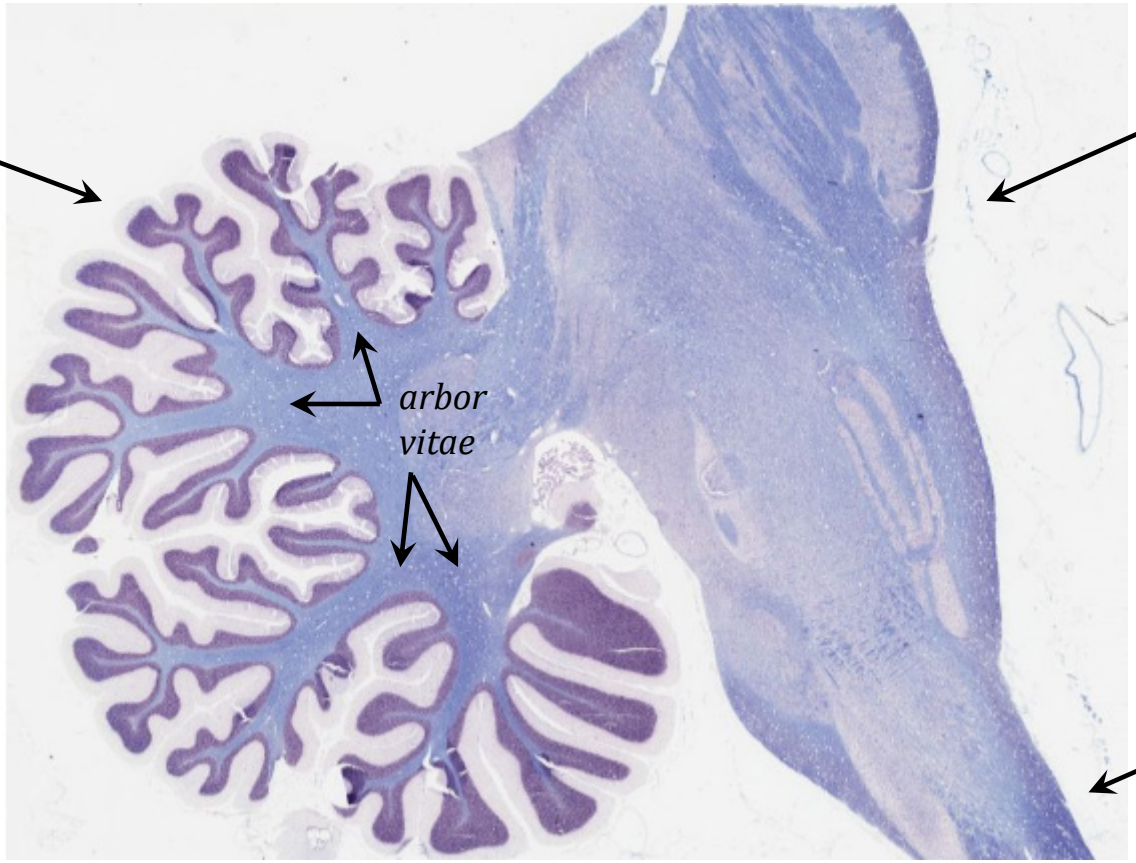

the **cerebellum** (Lt. "little brain") participates in the planning and coordination of movement; it has the same organization of grey matter on the outside and white matter on the inside as does the cerebral cortex; the branching white matter of the cerebellum is referred to as the *arbor vitae* (Lt. "tree of life")

Slide 71: Cerebellum, Cresyl Violet

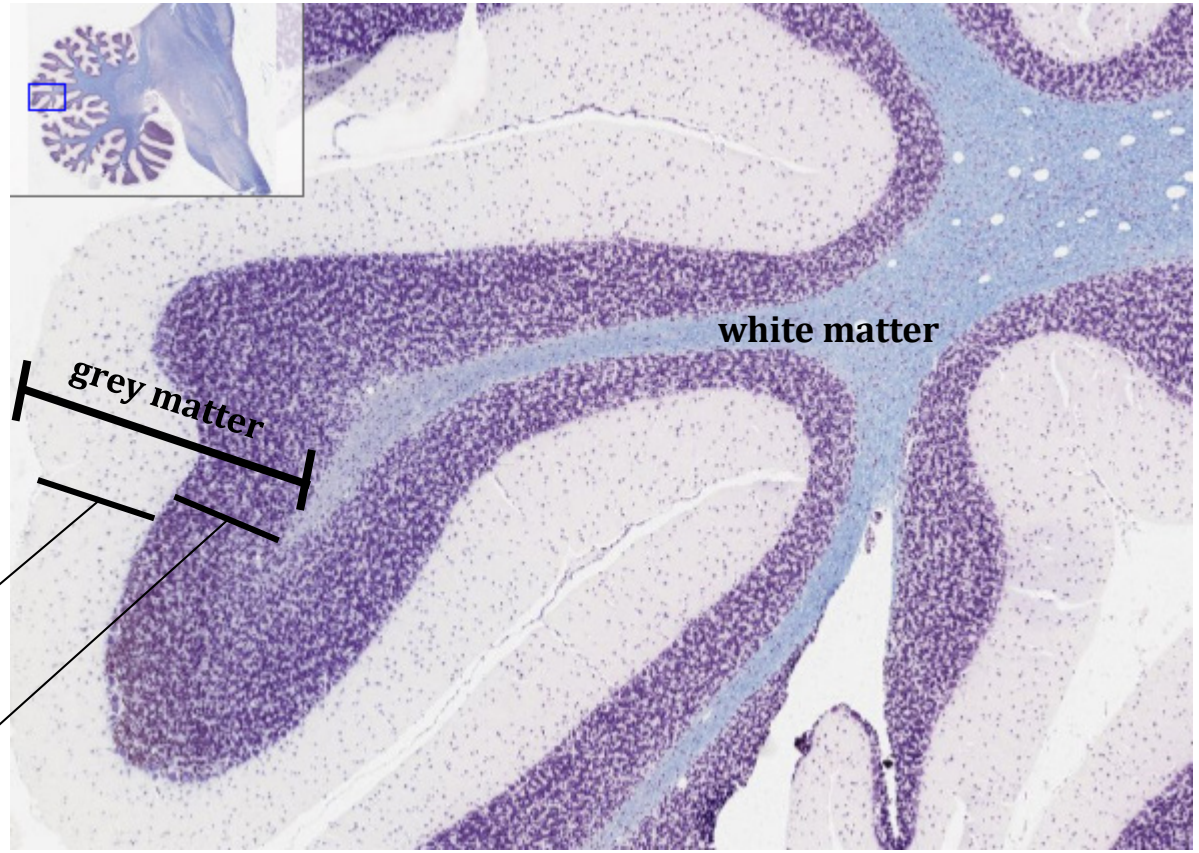

the **grey matter** of the cerebellum is further divided into three specific layers: the outermost **molecular layer**, the innermost **granular layer**, and a third **Purkinje cell layer** located between the two layers and consisting of a single cell layer of large Purkinje cell neurons

Lab 10 – Nervous Tissue

IUSM – 2016

Slide 148: Cerebellum, H&E

grey matter

molecular layer (light)

granular layer (dark)

Slide 71: Cerebellum, Cresyl Violet

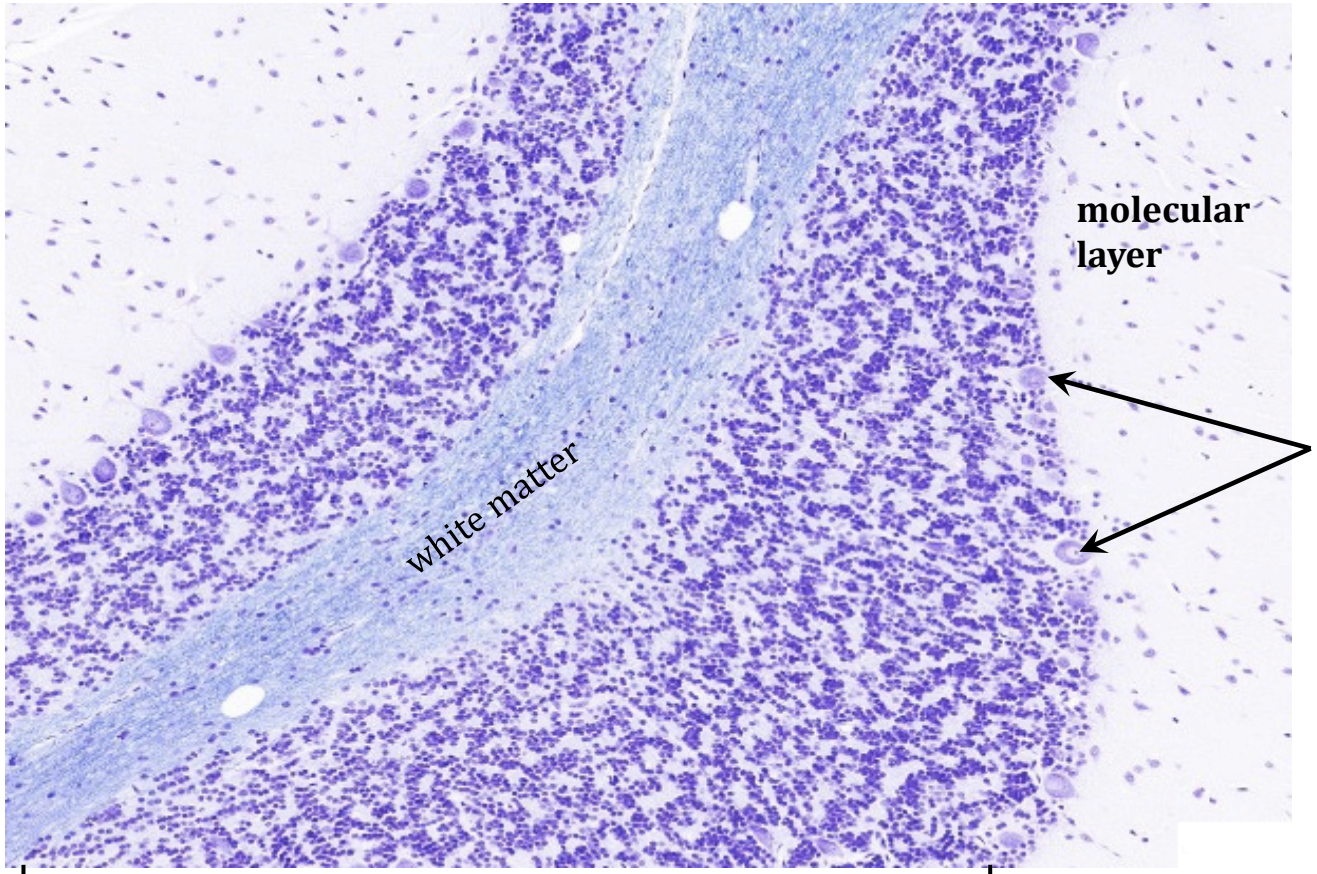

Purkinje cells separate the two layers

granular layer

of the **grey matter**, the inner **granular layer** is composed of several types of neurons including *granule cells*, the most numerous neurons in the brain (containing likely over half the total number of cells in the brain); the outer **molecular layer** is primarily neuropil, containing the axons of granular cells and the dendrites of **Purkinje cells**

Slide 71: Cerebellum, Cresyl Violet

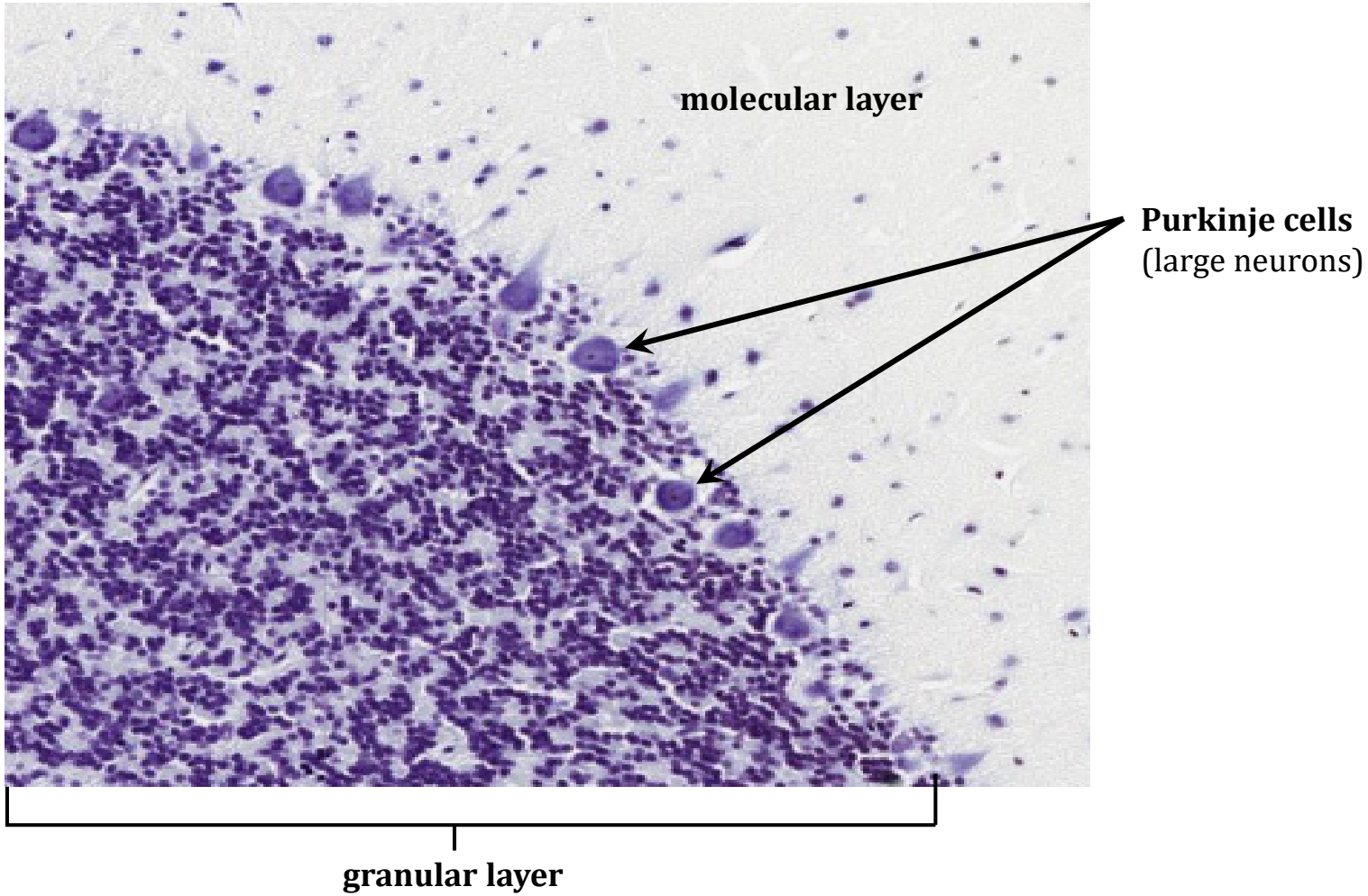

Purkinje cells (*not Purkinje fibers, which are found in the heart*) separate the molecular and the granular layers; each Purkinje cell may receive input from up to 200,000 granule cells – more synaptic input than any other cell type in the brain; axons of the Purkinje cells are the beginning of the pathway "out" of the cerebellum

Slide 71: Cerebellum, Cresyl Violet

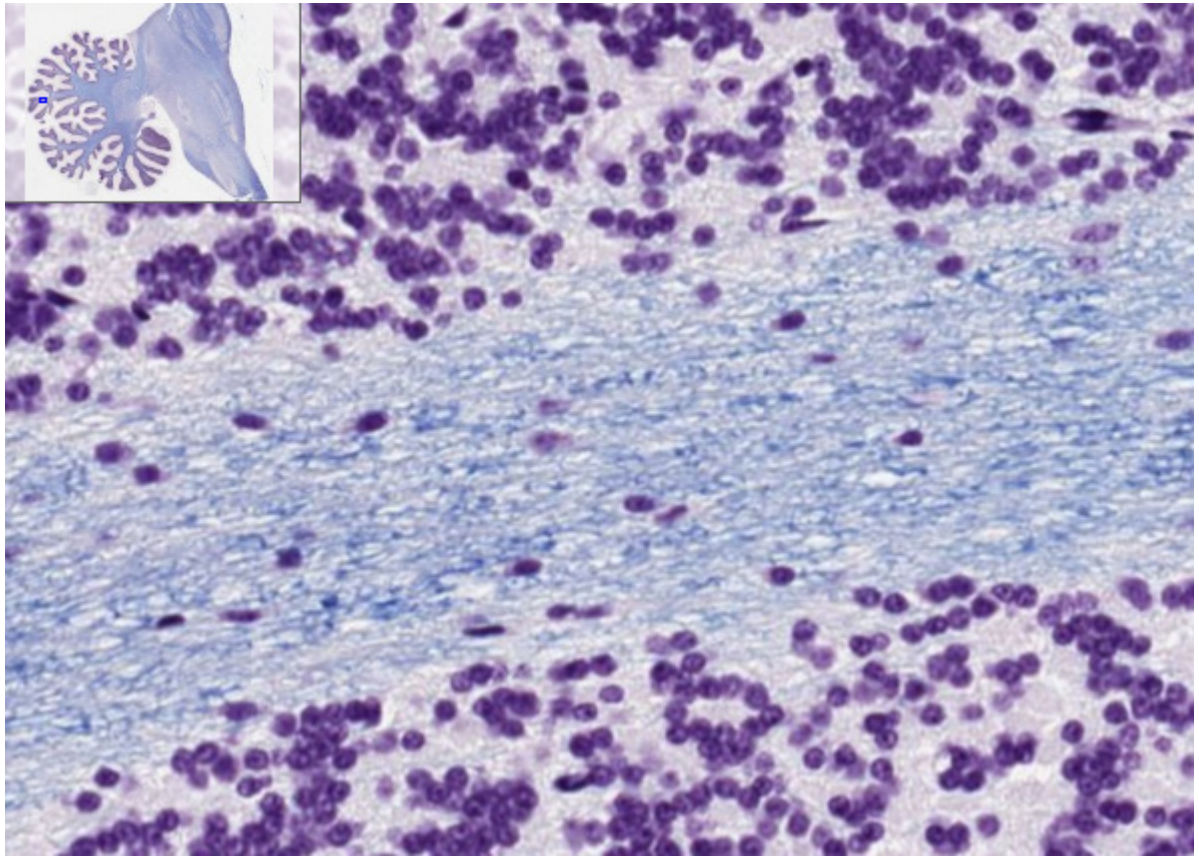

granular layer of grey matter

white matter

granular layer of grey matter

like elsewhere in the CNS, the **white matter** of the cerebellum consists primarily of a few glial cells (oligodendrocytes) and **myelinated axons** traveling to and from the grey matter

Slide 19a (464): Spinal Cord, Myelin Stain

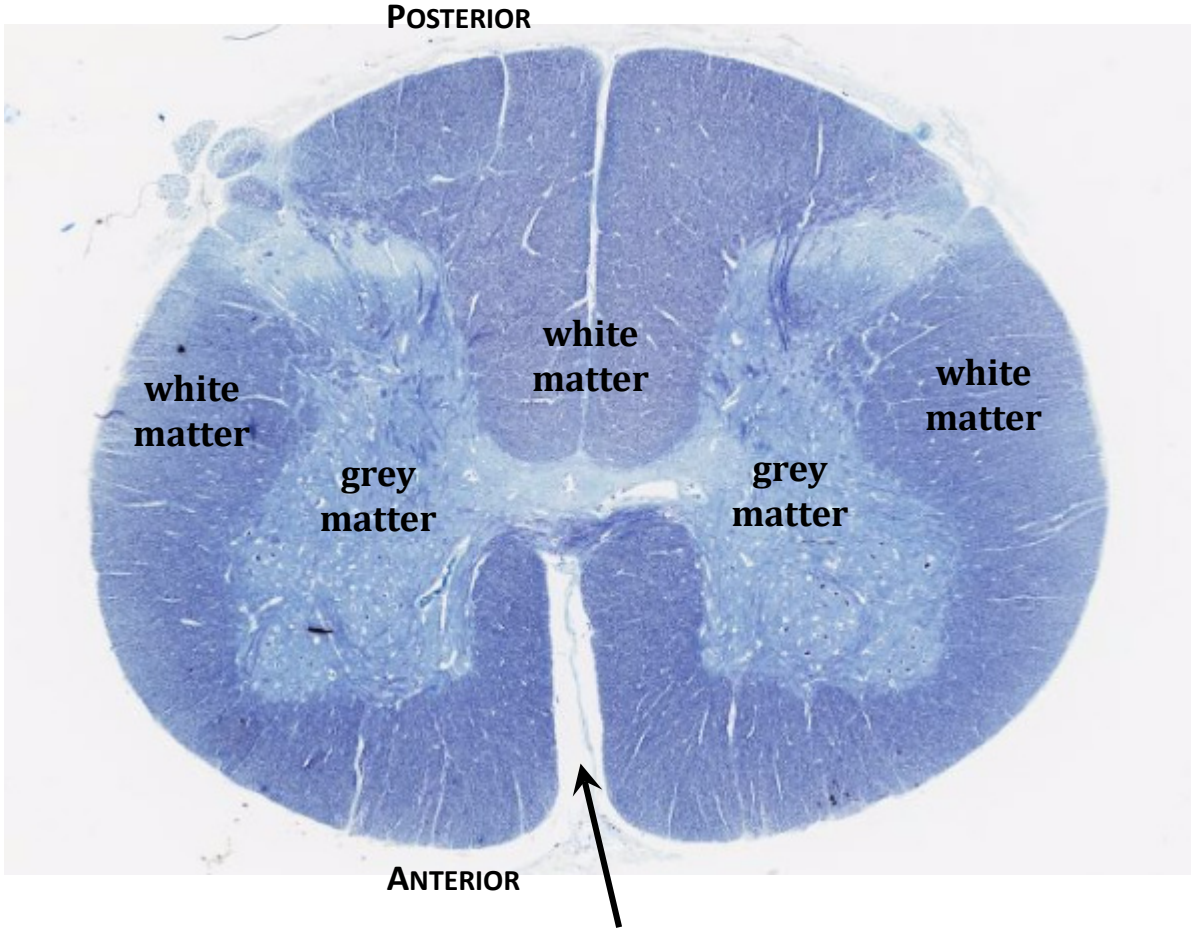

use the *anterior median fissure* to help distinguish the anterior (ventral) and posterior (dorsal) sides of the cord

a special myelin staining technique is used to visualize ***myelinated axons*** *which compose the majority of the* ***white matter****; thus, somewhat confusingly, white matter appears darker and the grey matter appears lighter*

Slide 19a (464): Spinal Cord, Myelin Stain

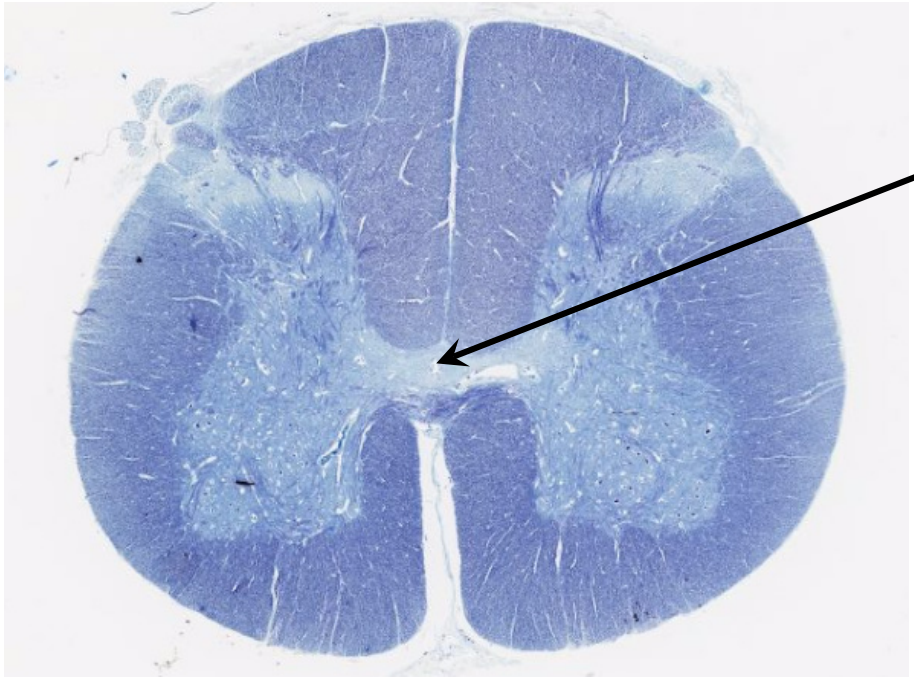

the **central canal** is the CSF-filled space (if it is not occluded) that runs longitudinally through the length of the entire spinal cord; in the medulla of the brainstem, the fourth ventricle narrows to become the central canal; the canal is the vestige of the embryologic neural tube and is considered functionless

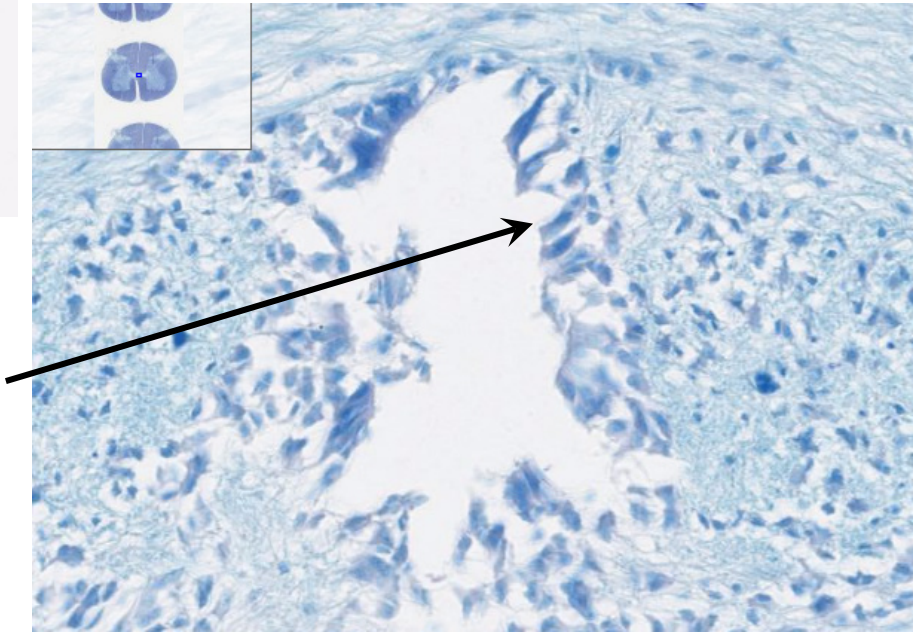

the **central canal**, like the *ventricles* in the brain, is lined by **ependymal cells**; they are epithelial-like cells which lack a basement membrane

Slide 19a (464): Spinal Cord, Myelin Stain

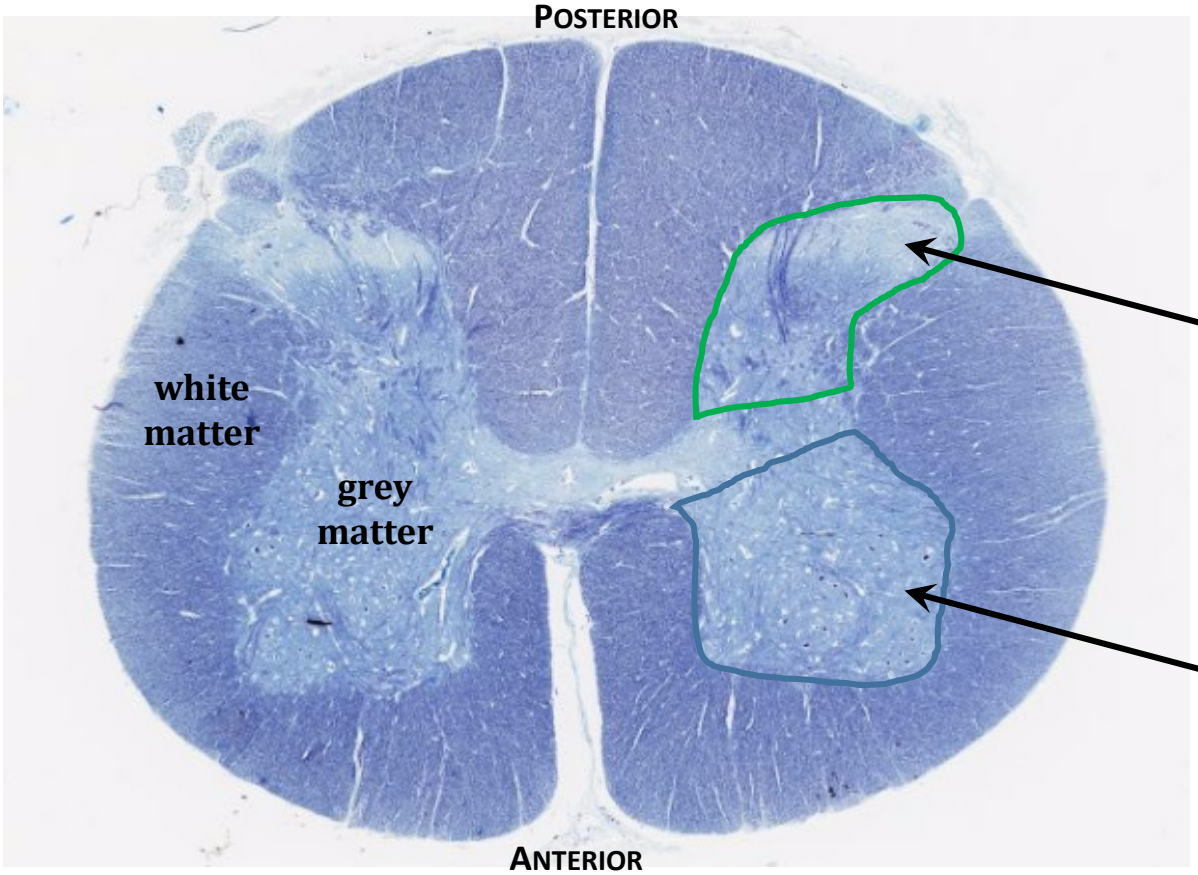

dorsal (posterior) horn contains the cell bodies of *sensory* neurons

ventral (anterior) horn contains the cell bodies of large *motor* neurons

the **grey matter** of the spinal cord is composed of neuron cell bodies, neuroglial cells, unmyelinated fibers, and a relatively-few myelinated axons; the outer **white matter** consists largely of tracts of myelinated axons

Slide 19a (464): Spinal Cord, Myelin Stain

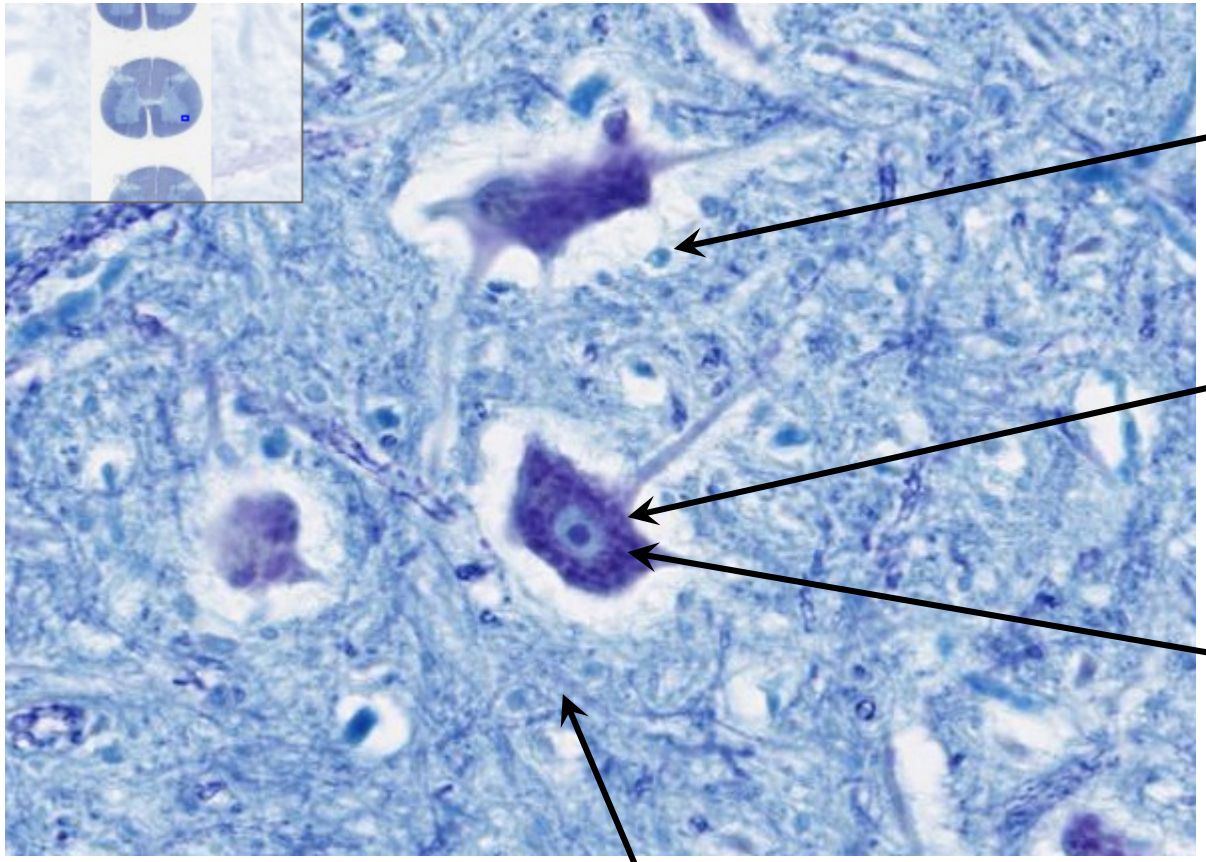

neuroglial cell

neuron cell body with a large pale-staining nucleus and prominent nucleolus

Nissl substance (rER) are the dark, basophilic blotches in the cytoplasm; it is not present in the hillock or axon

in the grey matter, **neuropil** is the meshwork of axonal, dendritic, and neuroglial processes between the neuron bodies (i.e., all the "stuff" between the cell bodies); it is not connective tissue

Slide 19a (464): Spinal Cord, Myelin Stain

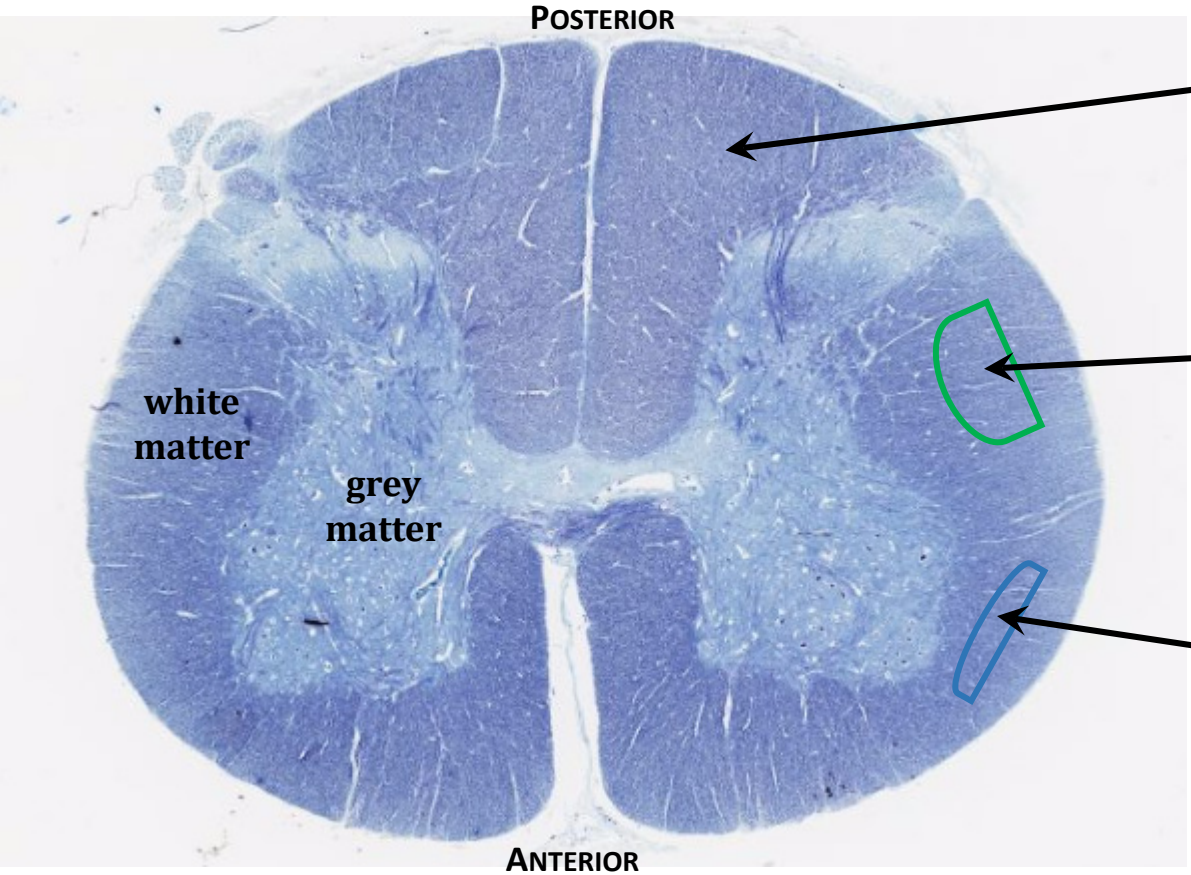

dorsal columns

ascending pathways carrying fine touch and proprioception sensory information from the spinal cord to the brain

lateral corticospinal tract

descending pathway carrying motor information from the brain to the spinal cord to synapse on motor neurons in the anterior horn which in turn innervate skeletal muscles

spinothalamic tract (ALS)

ascending pathway carrying pain and temperature sensory information from the opposite side of the body to the brain

the **white matter** consists largely of organized bundles of myelinated axons; by convention, it is divided into three major regions called *funiculi* (dorsal, lateral, and anterior); within the funiculi, smaller organized bundles of axons carrying specific sensory or motor information are called *fasciculi* (or tracts)

Slide 19a (464): Spinal Cord, Myelin Stain

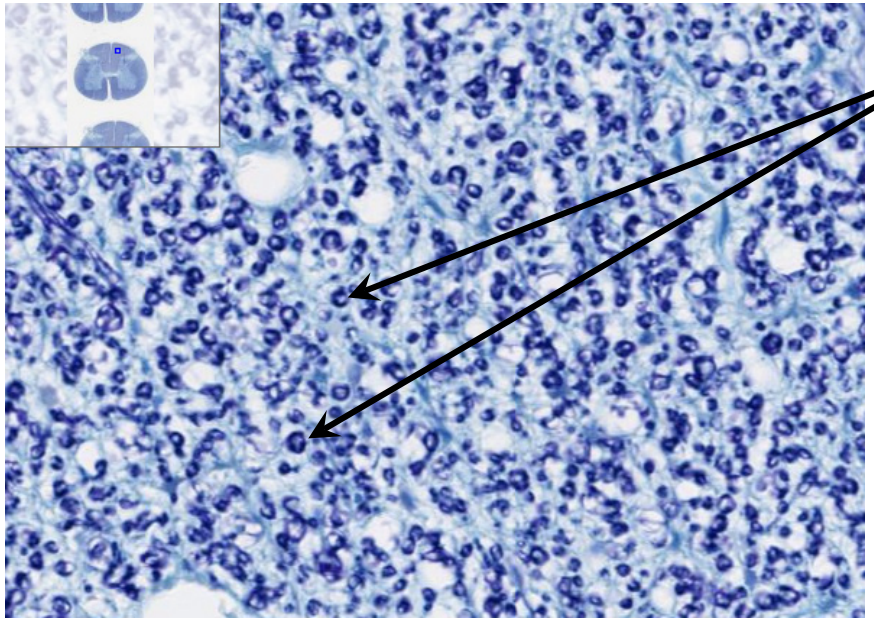

myelinated fibers of the white matter seen in cross-section; the myelin staining shows "rings" of myelin of the oligodendrocytes surrounding a central axon

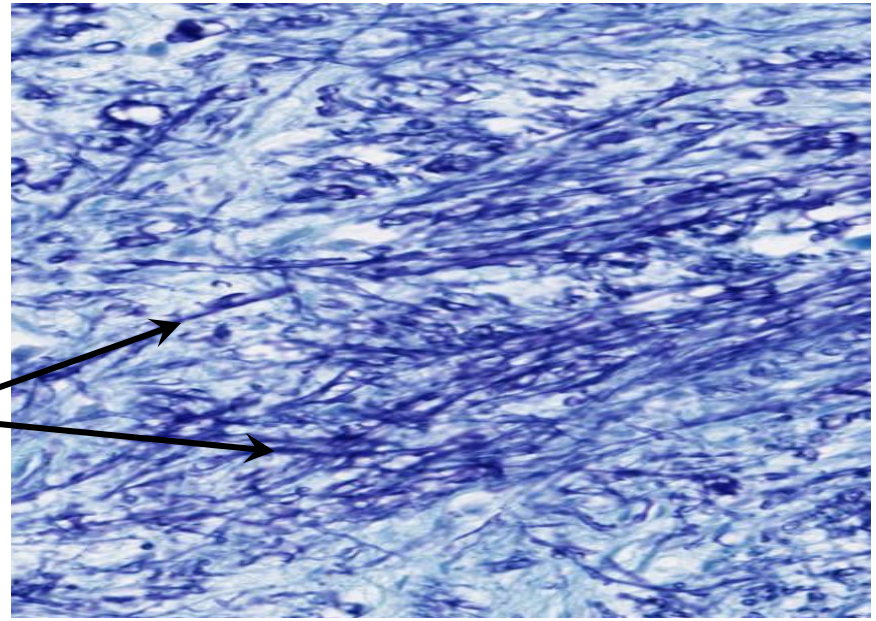

myelinated fibers seen longitudinally; this image is from the *anterior white commissure* where axons of the white matter cross from one side of the spinal cord to the other side; the nuclei of oligodendrocytes can also be seen

Lab 10 – Nervous Tissue

IUSM – 2016

Slide 9: Spinal Cord, H&E

Slide 57 (NW): Spinal Cord Sections

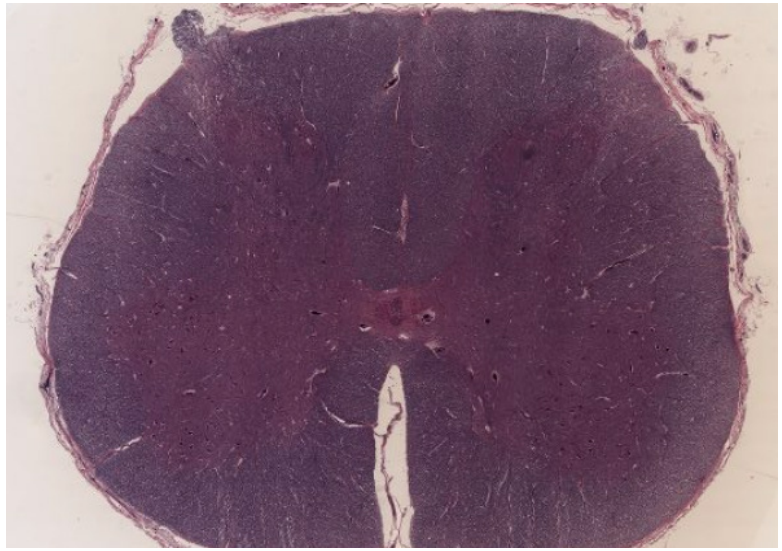

look at different spinal cord slides to be able to distinguish **grey matter** and **white matter** in different stains

Slide 50 (NW): Spinal Cord

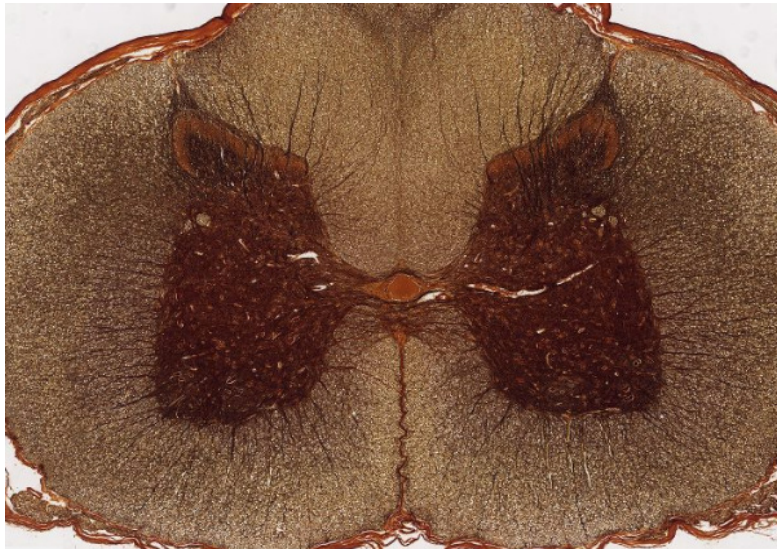

looking at the different slides, some of which contain several spinal cord sections, appreciate the difference in the relative amounts of grey matter and white matter from different regions of the spinal cord

Lab 10 – Nervous Tissue

IUSM – 2016

Slide 137: Dorsal Root Ganglia, H&E

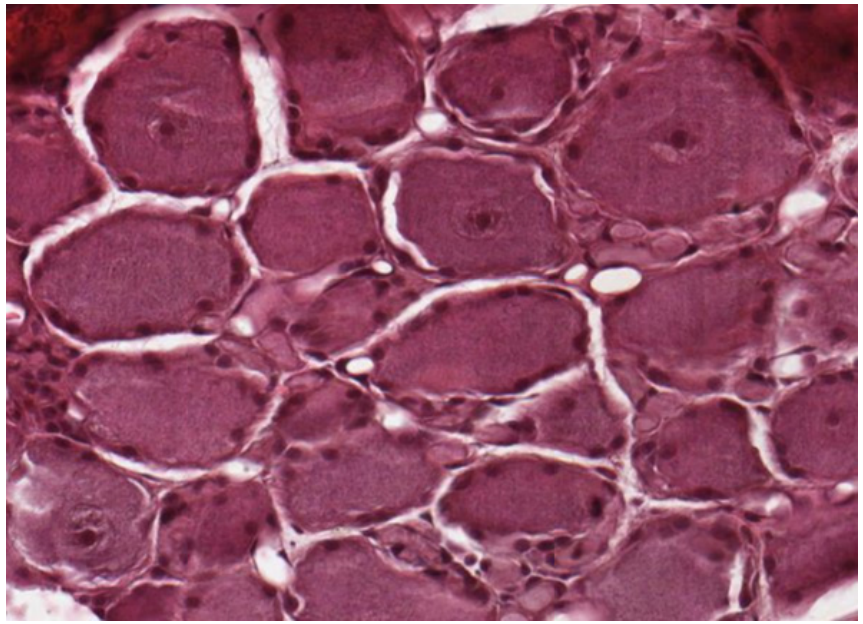

sensory (**dorsal root**) **ganglion** with many large, tightly-packed *pseudo-unipolar neurons*; the neurons are surrounded by many smaller satellite cells (neuroglial cells)

Slide 135: Sympathetic Ganglion, H&E

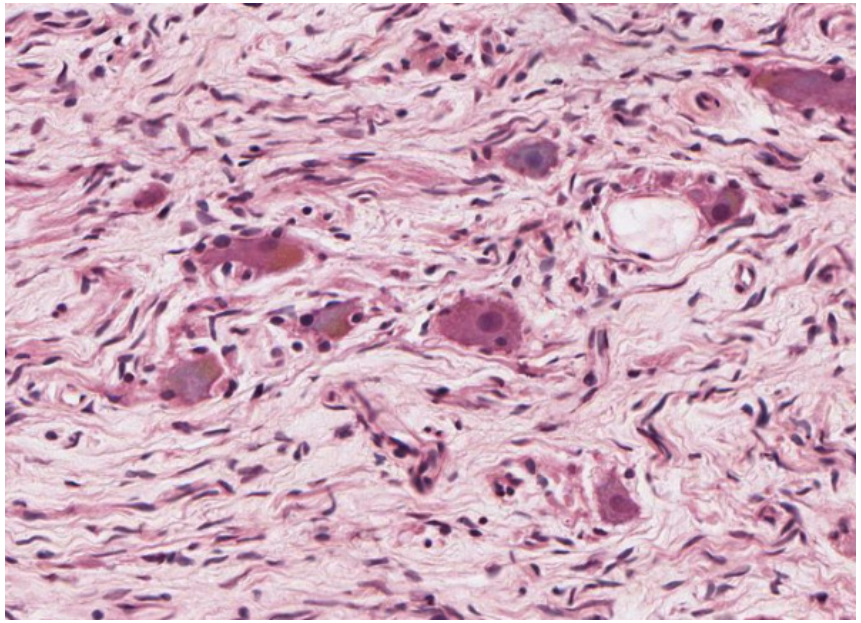

sympathetic (**autonomic**) **ganglion** with less tightly-packed *multipolar neurons*; the neurons are surrounded by small satellite cells (neuroglial cells)

a **ganglion** (pl. ganglia) is a collection of nerve cell bodies outside of the CNS; there are two major types based upon the function of their neurons: **sensory ganglia** contain sensory neurons and are located along the dorsal roots of the spinal cord; **autonomic ganglia** contain motor neurons and are located either in the *sympathetic trunk*, adjacent to the vertebral bodies, or in, or near, the organs they innervate (*parasympathetic*)

Slide 137: Dorsal Root Ganglia, H&E

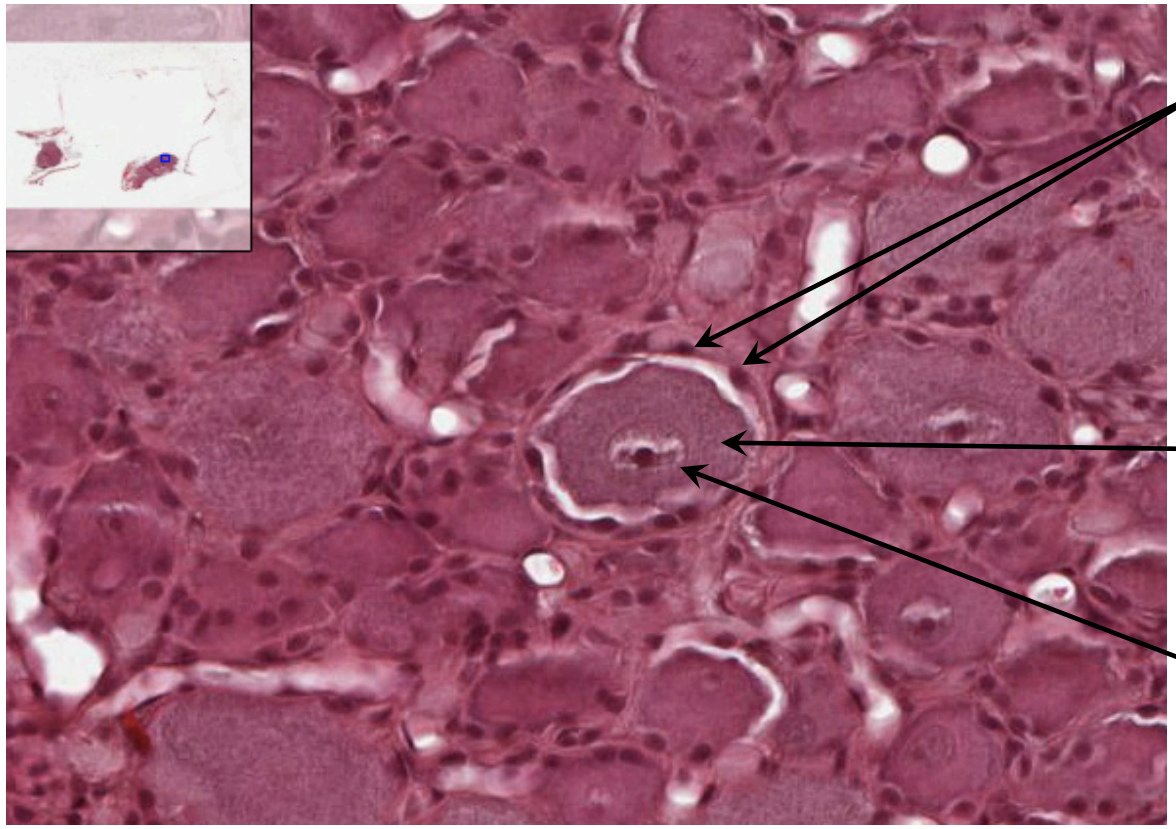

satellite cells
are neuroglial cells that surround and support neuron cell bodies in ganglia

note that both "s" neuroglial cells (satellite and Schwann) are found in the PNS (i.e., to the side)

neuron cell body
sensory neurons are *pseudo-unipolar* so are able to pack tightly together

nucleus of neuron with prominent nucleolus; the nuclei of many of the neurons are not visible due to sectioning

sensory (**dorsal root**) **ganglia** are located on the dorsal roots of the spinal cord; they contain large, pseudo-unipolar sensory neurons; the axons of the neurons principally carry information from the periphery (e.g., tactile receptors in the skin) to neurons in the spinal cord or brainstem; there are no synapses within these ganglia – the information merely "passes through" along the axons, which can be very long; arguably the longest cells in the body are the sensory neurons with axons from the great toe to the sensory ganglia of the lower lumbar spine, a distance easily over 4ft in many adults

Lab 10 – Nervous Tissue

IUSM – 2016

Slide 9: Spinal Cord, H&E

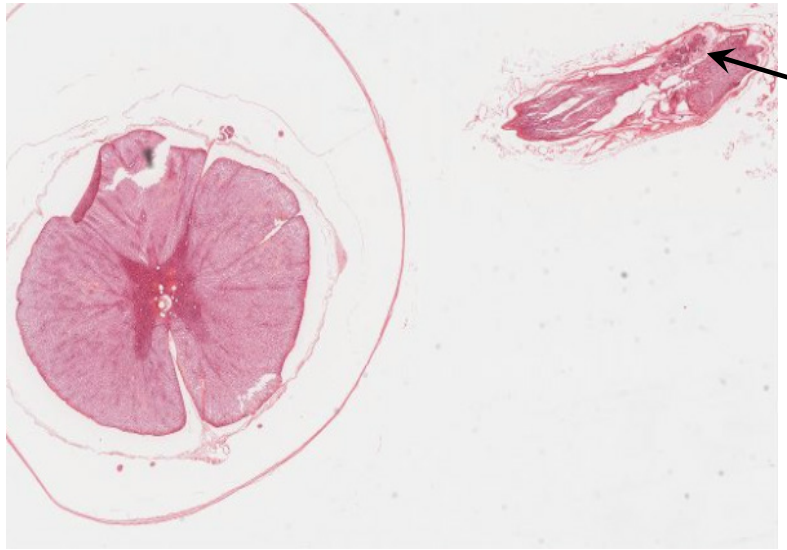

look here to see a **dorsal root ganglion**; notice its position relative to the spinal cord

Slide 21 (464): Spinal Ganglion

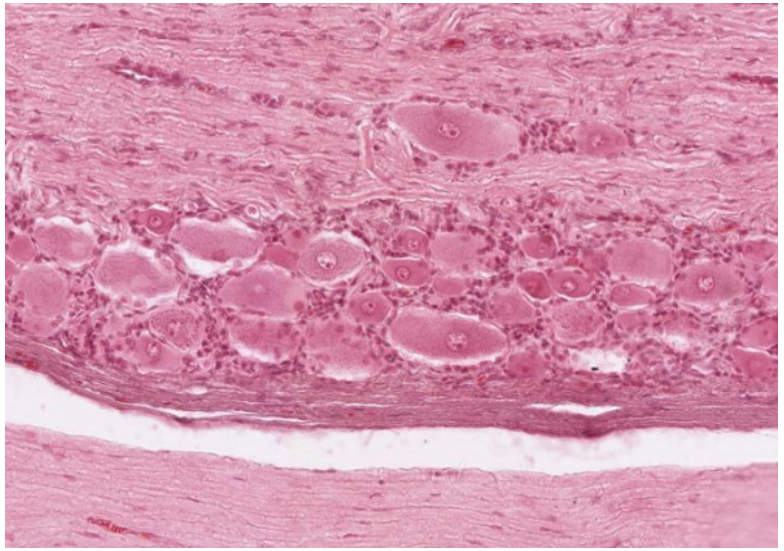

Slide 50 (NW): Spinal Ganglion

look here to see a **dorsal root ganglion** and trace its fibers as they enter into the spinal cord

Slide 135: Sympathetic Ganglion, H&E

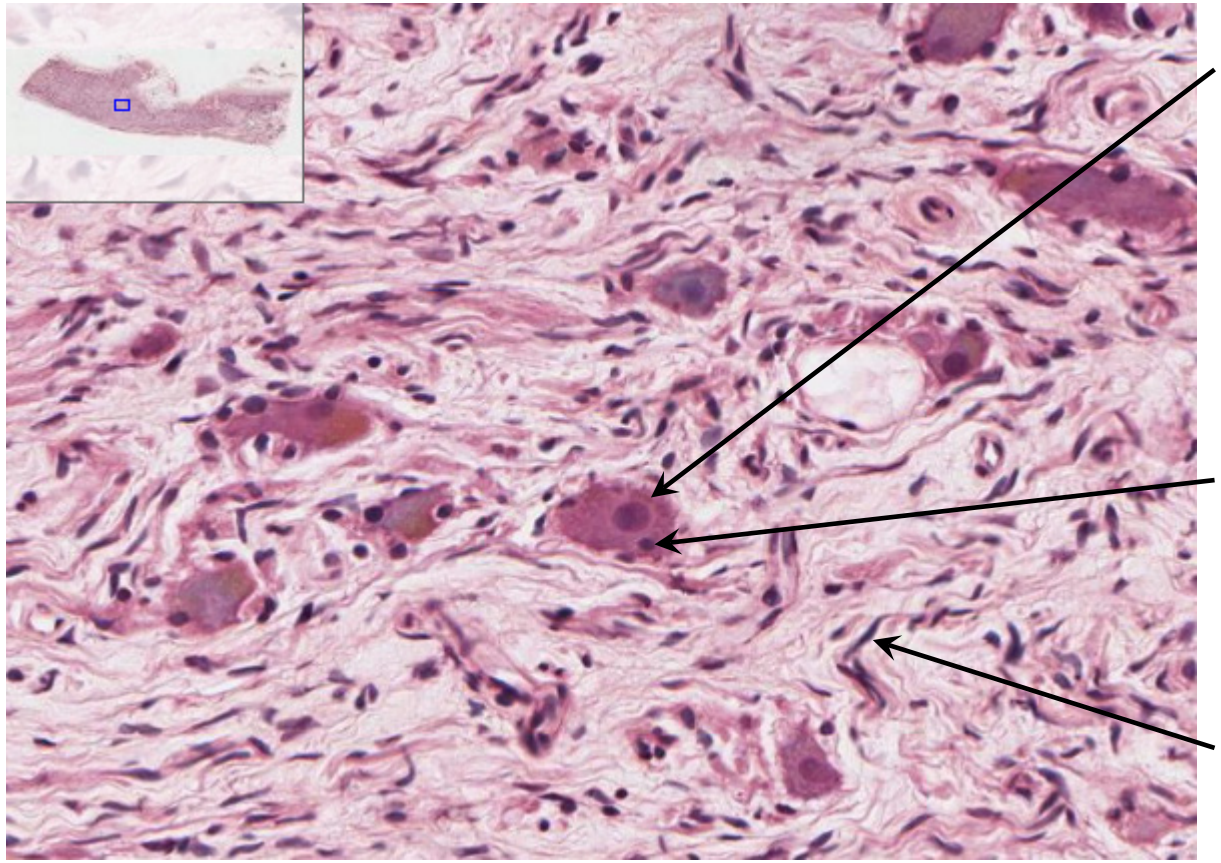

neuron cell body
autonomic motor neurons are *multipolar* so do not pack as tightly; there is a prominent nucleus and nucleolous

notice the presence of lipofuscin in some of the neurons

satellite cells
are neuroglial cells that surround and support neuron cell bodies in ganglia

Schwann cells and a few fibroblasts surround the nerve fibers

autonomic ganglia contain multipolar motor neurons of the autonomic nervous system; unlike sensory ganglia, autonomic ganglia are synaptic sites, with *pre-ganglionic* axons (generally from neurons in the spinal cord) synapsing upon the ganglionic neurons; the ganglionic neurons then send their axons (*post-ganglionic*) out to their target effectors (e.g., smooth muscle of viscera); **sympathetic ganglia** are generally located in the *sympathetic trunk*, an interconnected string of ganglia adjacent to the bodies of the vertebrae

Lab 10 – Nervous Tissue

IUSM – 2016

Slide 37: Ileum, H&E

look between the smooth muscle layers of the *muscularis* of the GI tract to find the *myenteric plexus* (or *Auerbach's plexus*) containing small **parasympathetic ganglia**

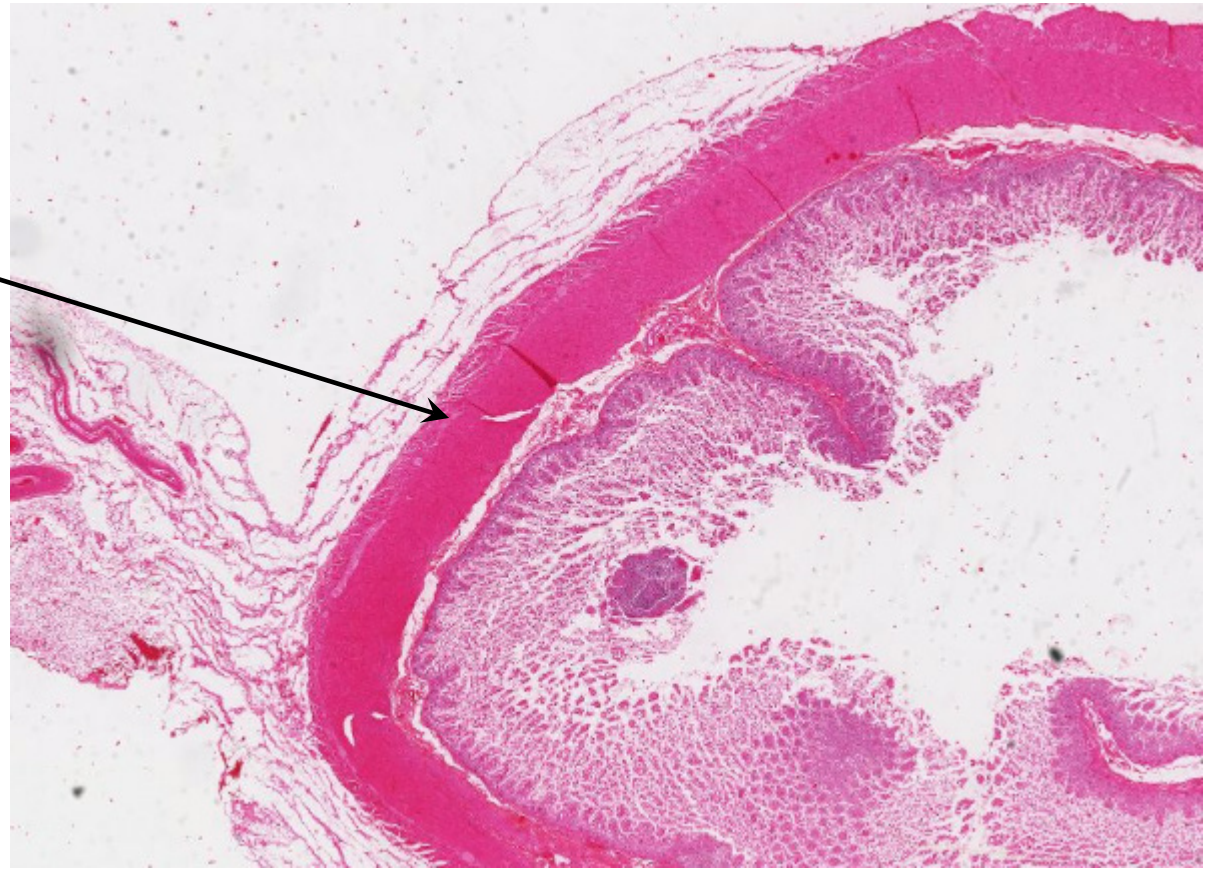

Slide 37: Ileum, H&E

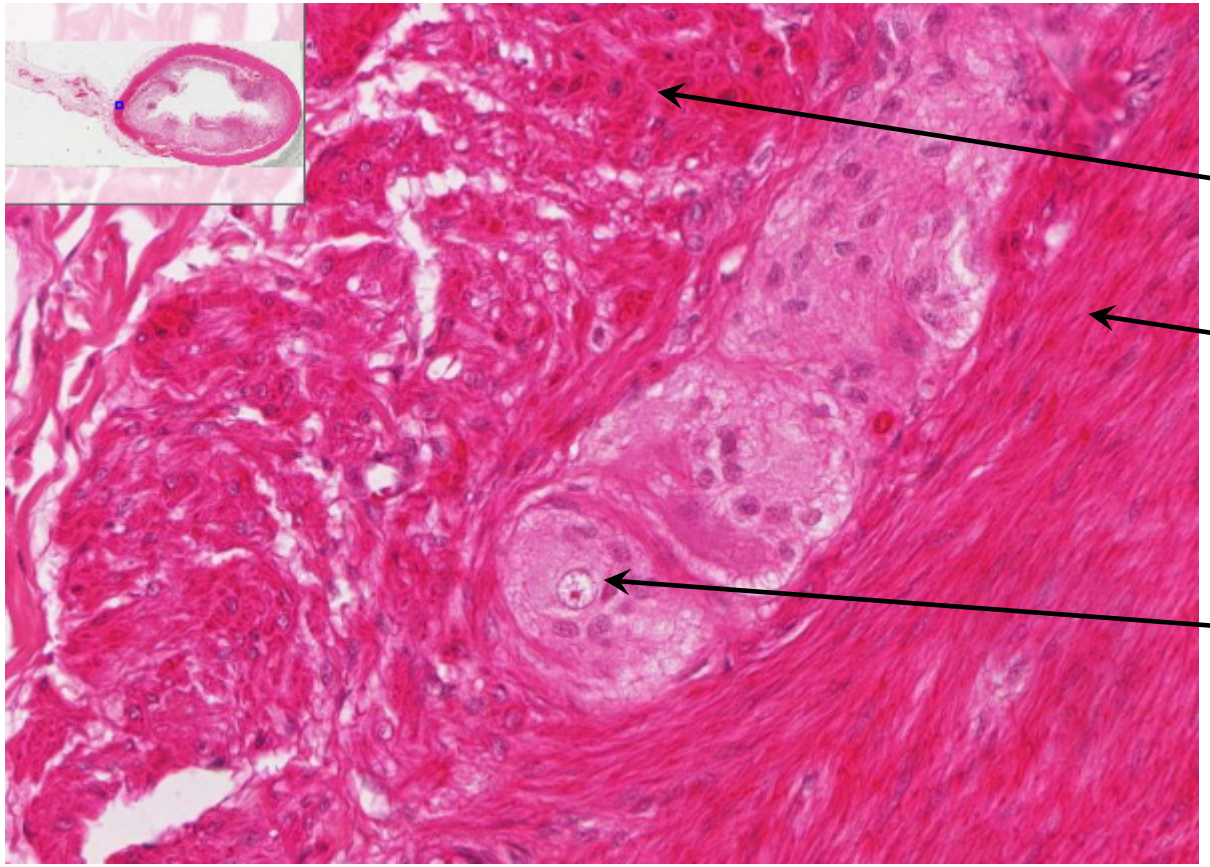

smooth muscle (cross-section)

smooth muscle (longitudinal-section)

neuron cell body
motor neuron surrounded by small satellite cells; the nucleus and nucleolus of the neuron are prominent

unlike sympathetic ganglia, **parasympathetic ganglia** are generally located either in, or close to, their target organs, so the pre-ganglionic axons tend to be longer than those of sympathetic ganglia, while the post-ganglionic axons are shorter

Lab 10 – Nervous Tissue

IUSM – 2016

Slide 117: Adrenal and Ganglion

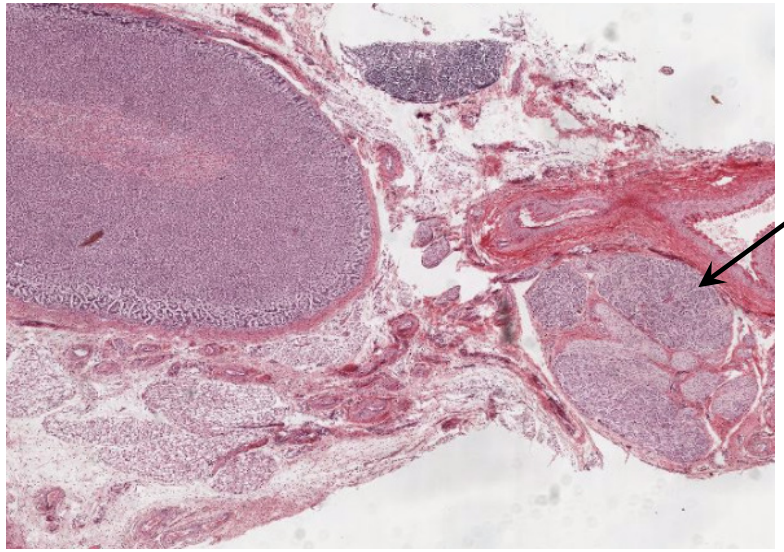

look here to see **autonomic ganglion**

Slide 52 (NW): Sympathetic Ganglion

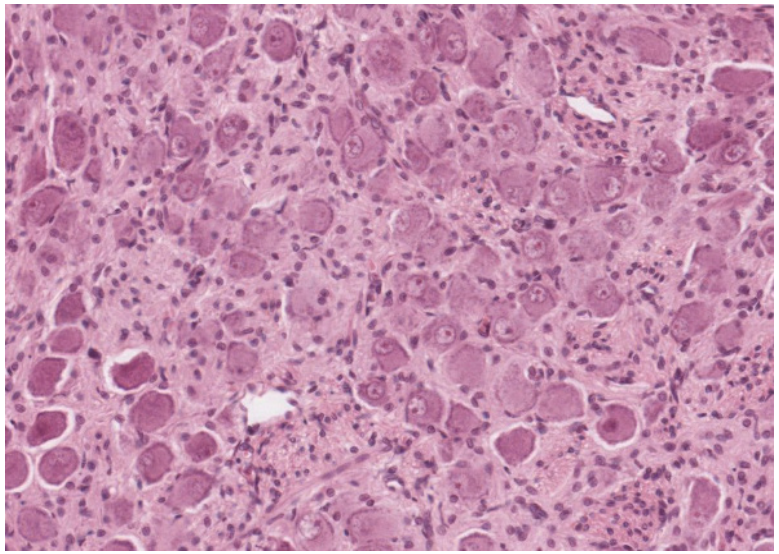

Slide 45: Autonomic Ganglion

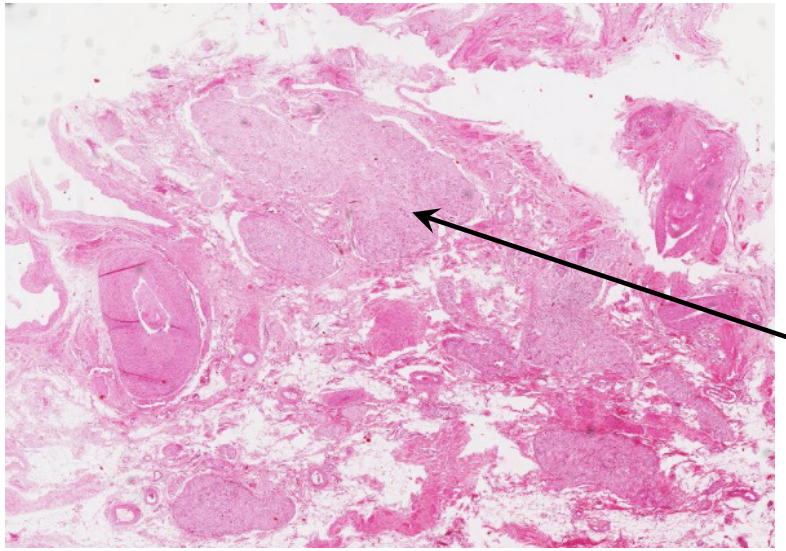

look here to see **autonomic ganglion**

Slide 8 (464): Mesentery, H&E

Slide Overview

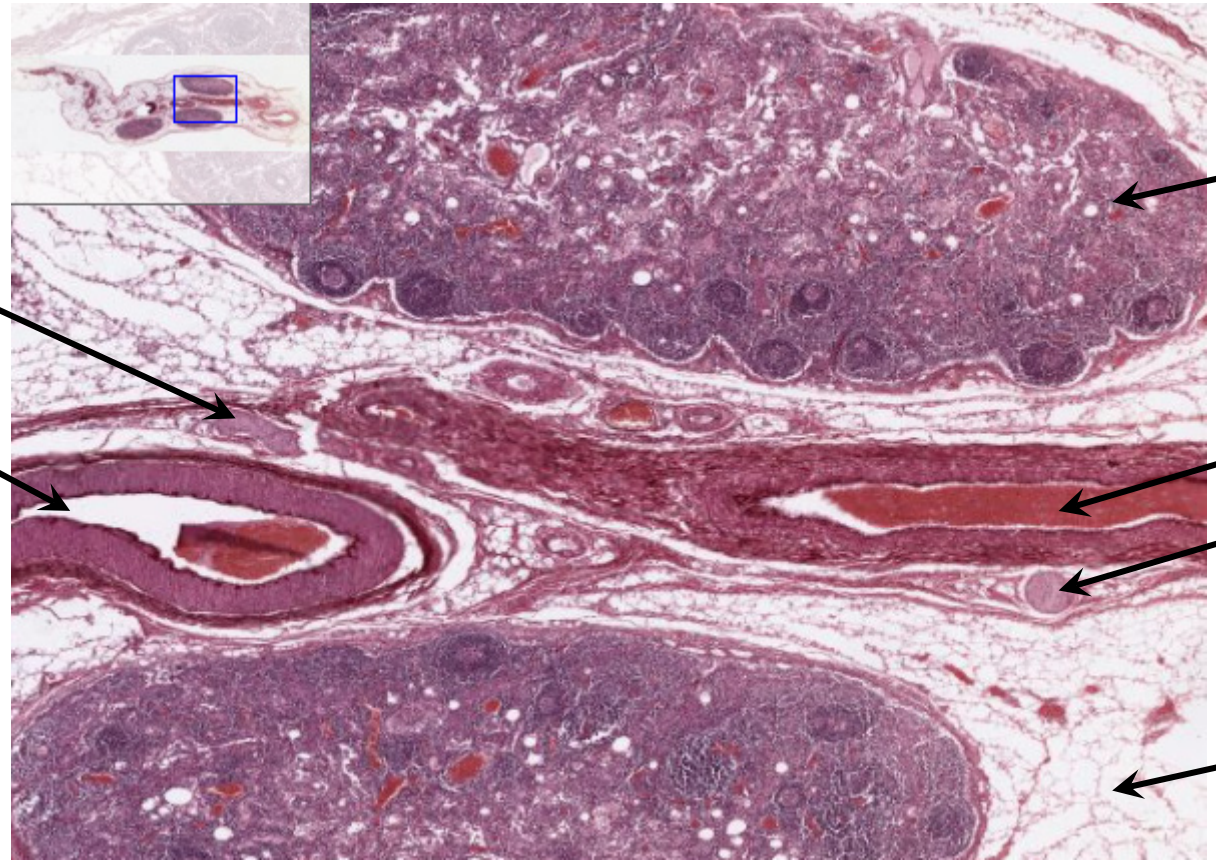

a *neurovascular bundle* is a collection of nerves, arteries, veins and lymphatics that tend to travel together in the body; they can be seen at both the gross and microscopic levels; on the slide shown above, small **peripheral nerves** can be seen alongside the vasculature

Slide 90 (NW): Artery, Vein, and Nerve

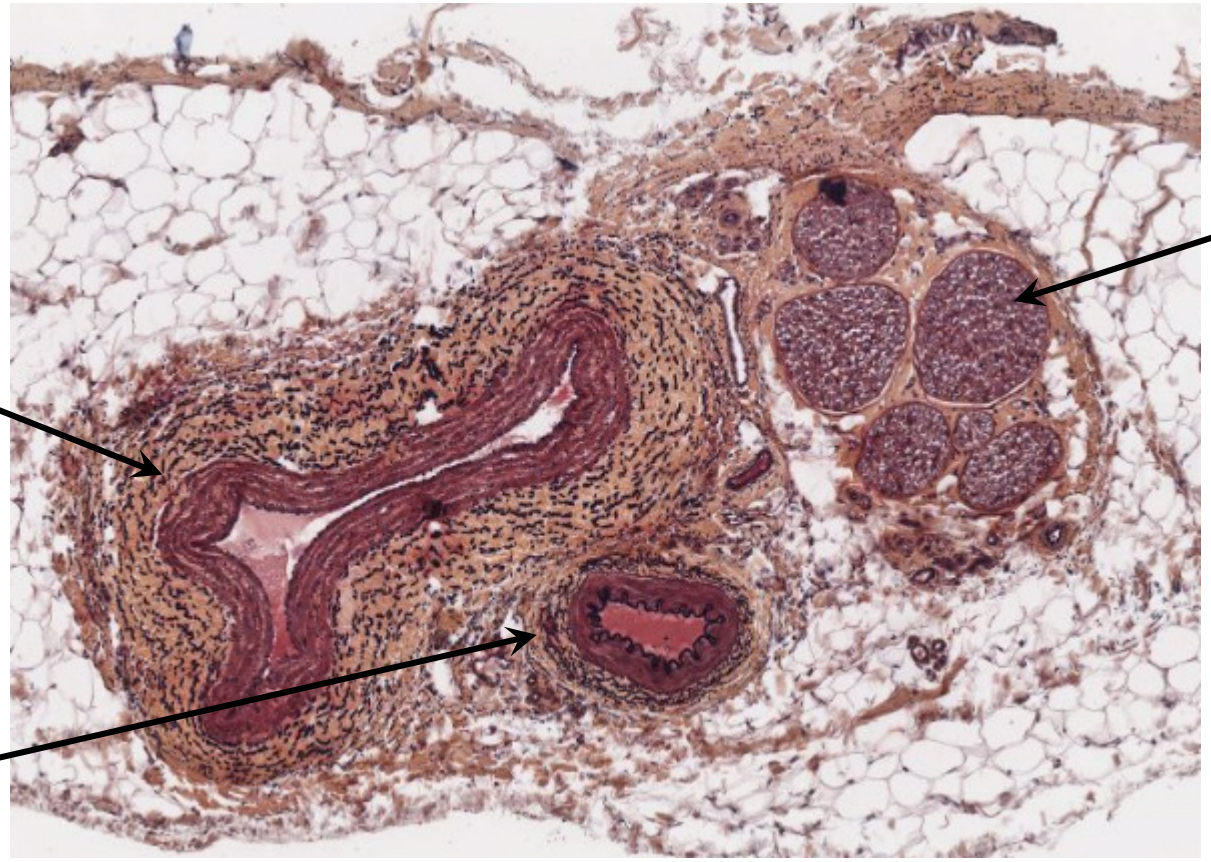

Slide 19 (464): Peripheral Nerve, H&E

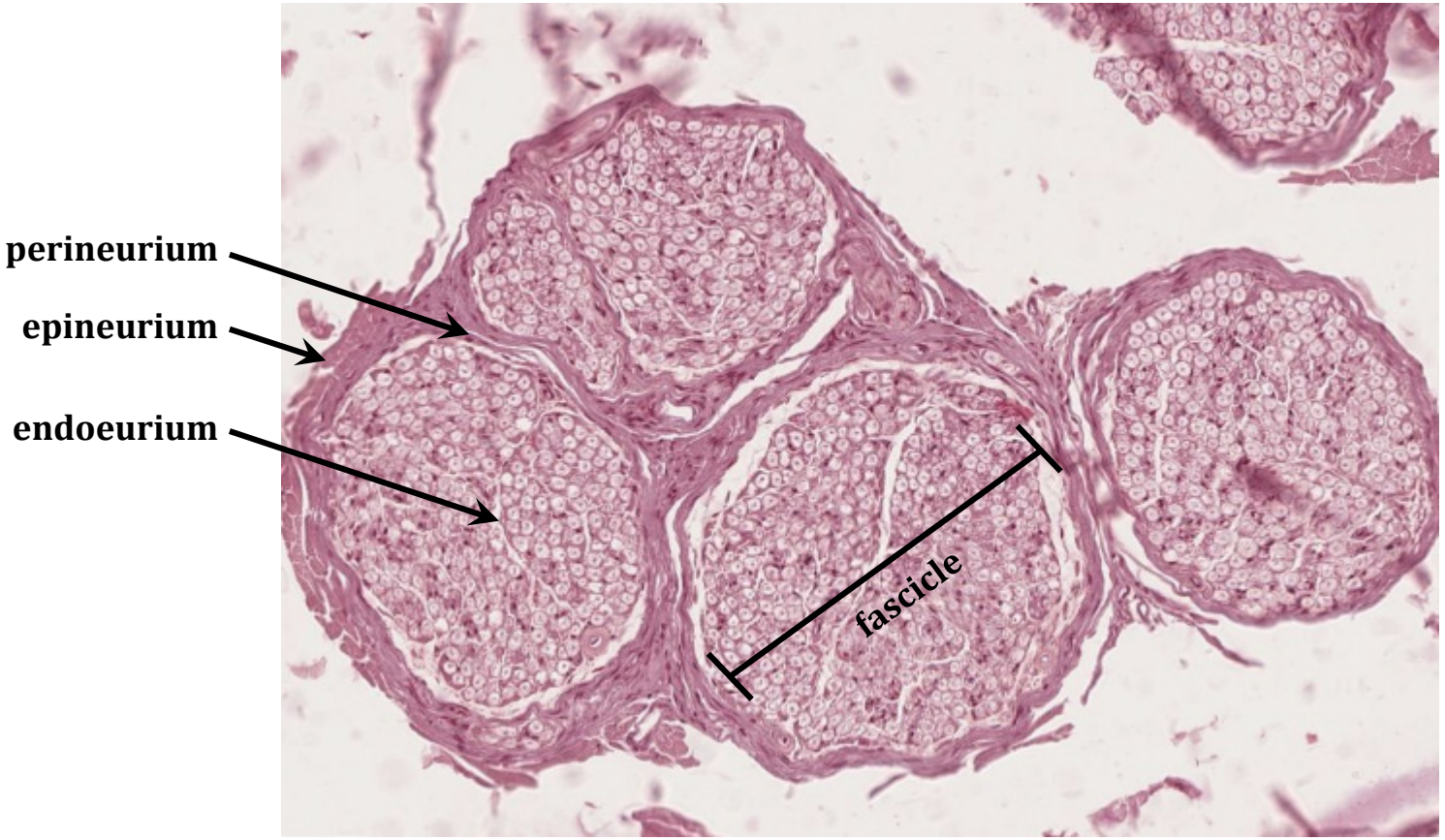

seen in cross-section, a **peripheral nerve** has organization similar to skeletal muscle; individual nerve fibers (myelinated and unmyelinated) are surrounded by a thin layer of CT called **endoneurium**; a group of nerve fibers form a *fascicle* which is surrounded by a specialized layer of cells called the **perineurium** that forms the *blood-nerve barrier*; surrounding an entire nerve (a group of fascicles) is dense CT called **epineurium**

Slide 19 (464): Peripheral Nerve, H&E

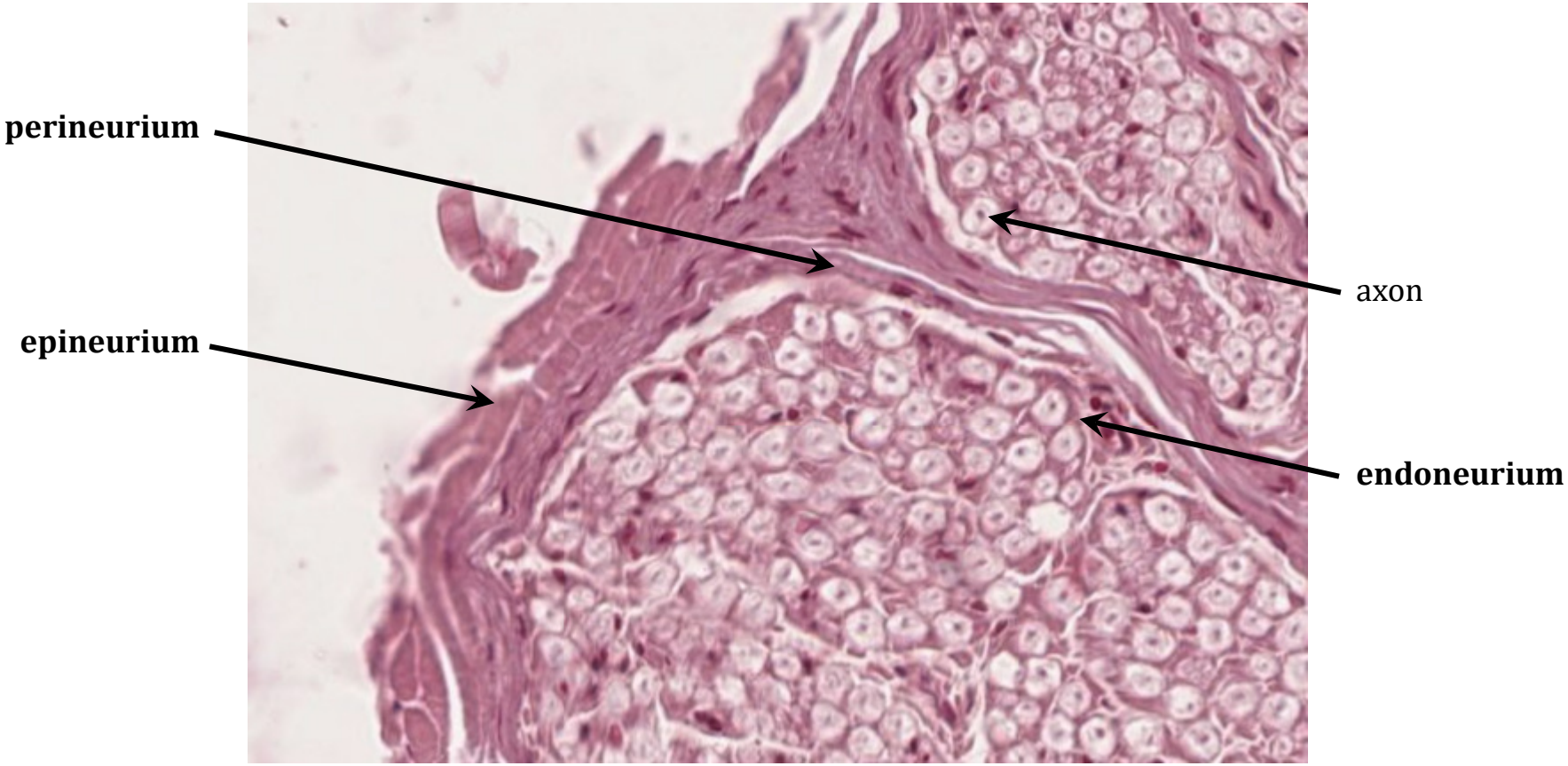

Slide 150: Peripheral Nerve, Osmium

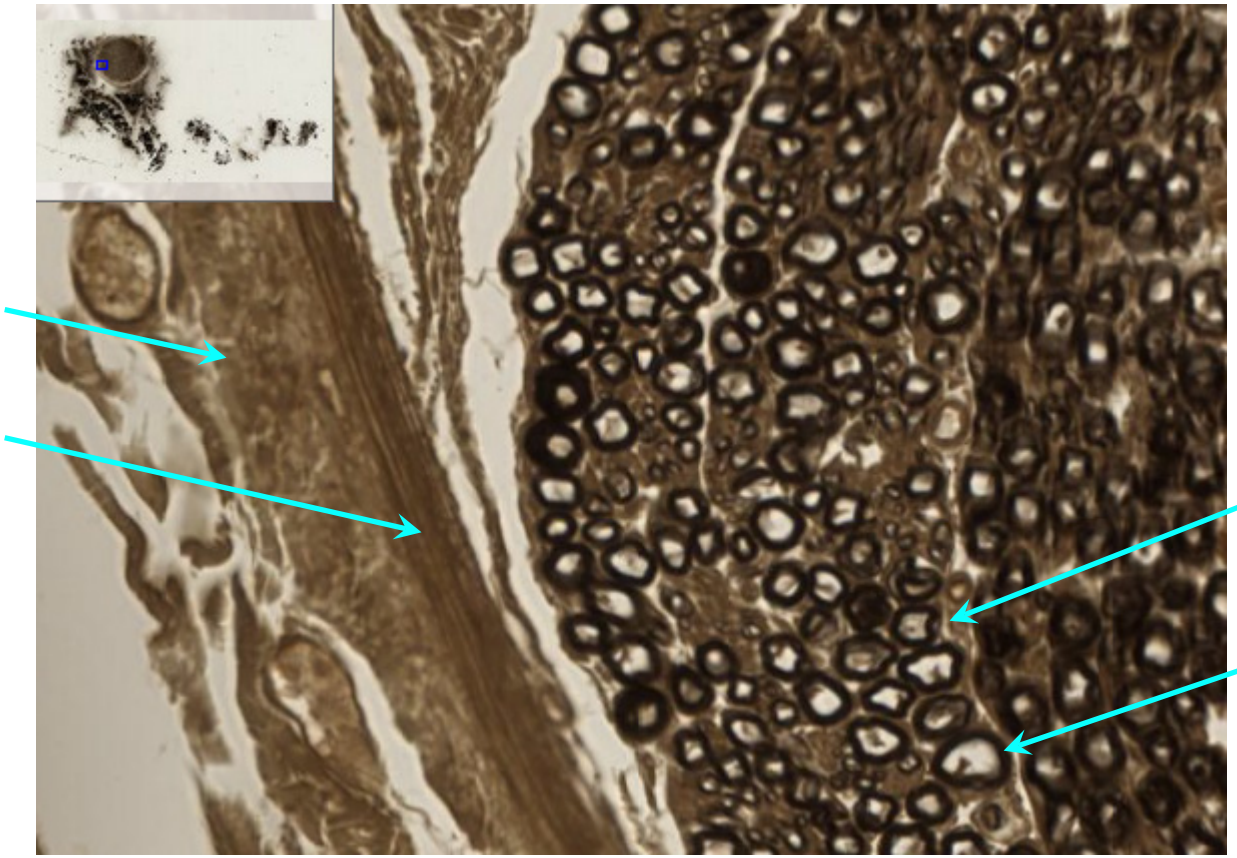

osmium stains lipids black so provides a useful way to see the **myelin sheaths** surrounding axons in peripheral nerves; myelination is the result of **Schwann cells** (a type of neuroglial cell) wrapping their plasma membranes many times around an individual axon – the lipid of the membrane then stains with the osmium and permits visualization

Slide 45: CT and Autonomic Ganglia, H&E

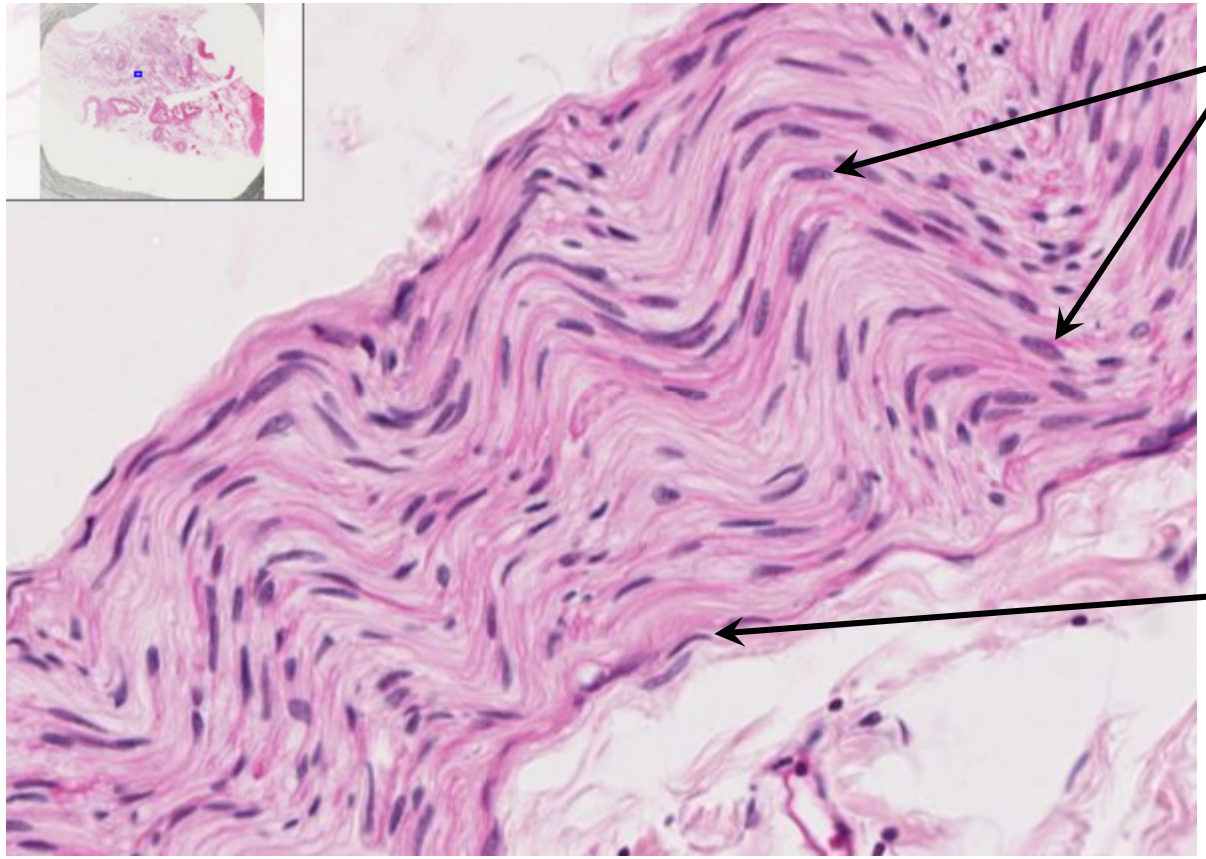

Schwann cells are the principal support cells (neuroglial cells) of the PNS; they enclose all axons in the PNS, and around large axons they produce myelin sheaths; they generally have a larger, more ovoid nucleus than fibroblasts and surround the paler-staining nerve axons

fibroblasts synthesize and maintain the **perineurium** and **endoneurium**; they appear as flattened cells associated with the darker-staining collagen fibers

seen in longitudinal-section, a **peripheral nerve** typically appears heterogeneous and pale-staining with a distinctive "wavy" appearance, which helps in distinguishing it from other tissue types such as smooth muscle or dense connective tissue

Slide 151: Nerve Fibers, H&E

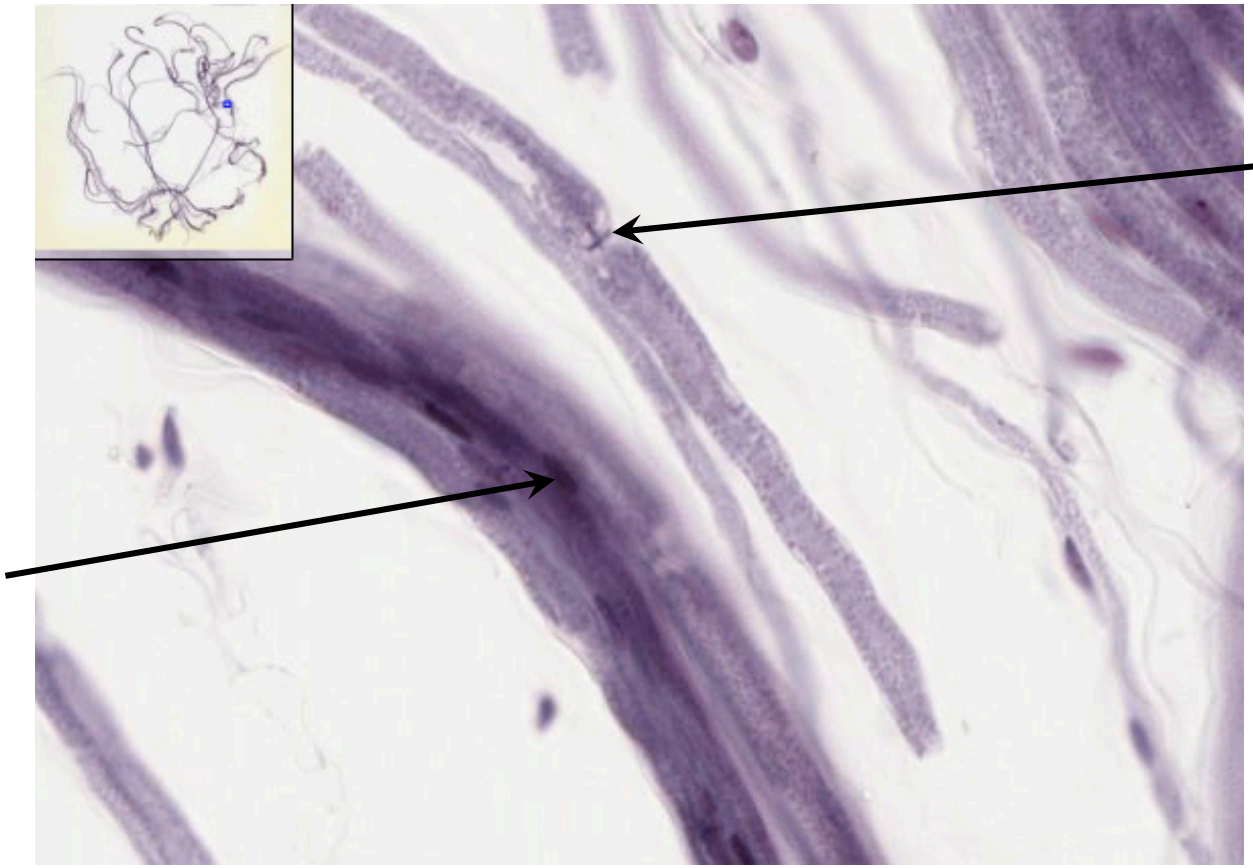

nodes of Ranvier (ron-vee-ay) are small gaps occurring along the length of an axon at the edges of two myelin sheaths from different **Schwann cells**; these small myelin-free areas along the axon permit ion exchange and fast impulse propagation (*saltatory conduction*); the nuclei seen are primarily all Schwann cells as the nuclei of the nerve cells are located either within the CNS or in ganglia

Lab 10 – Nervous Tissue

IUSM – 2016

Slide 57 (NW): Nerve Fibers, H&E

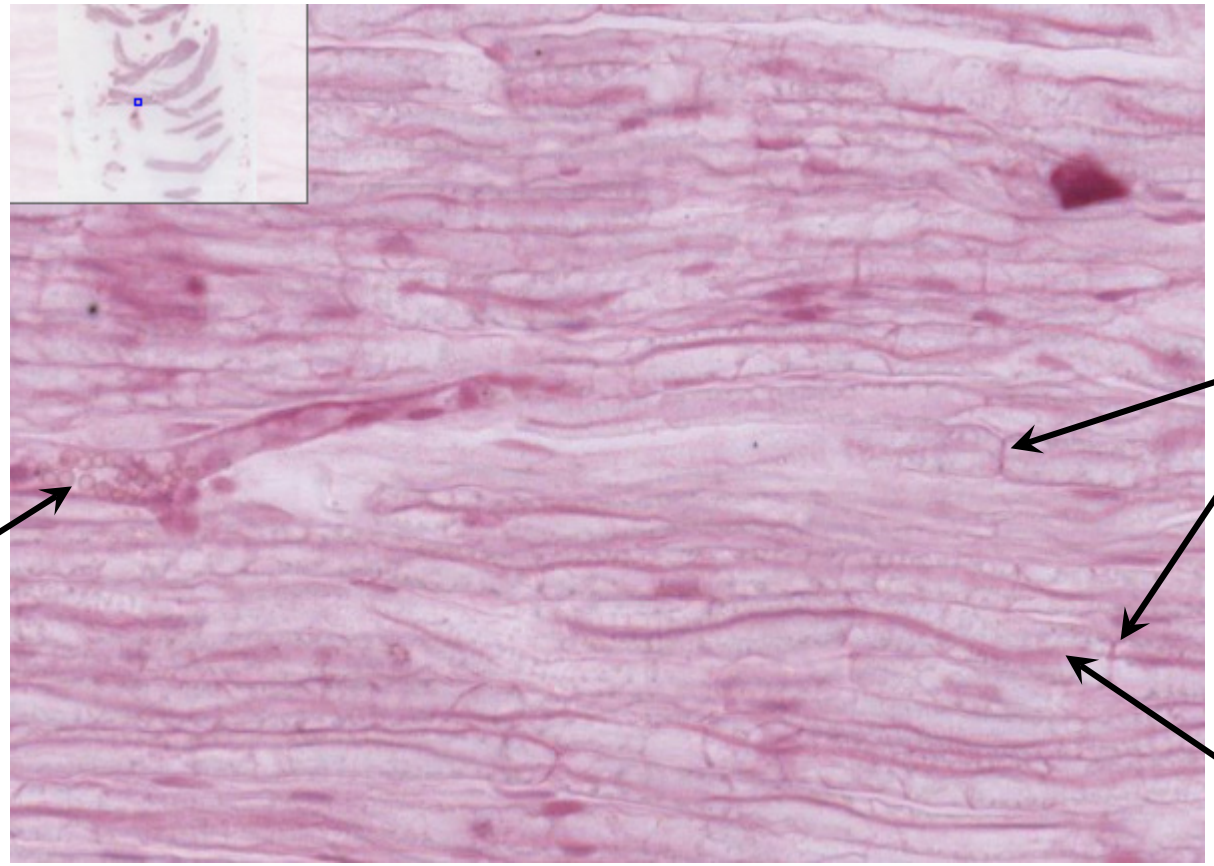

capillary

nodes of Ranvier

darker-staining **axon** surrounded by pale-staining **myelin sheaths**

Lab 10 – Nervous Tissue

IUSM – 2016

Common Confusion:
Smooth Muscle vs. Peripheral Nerve

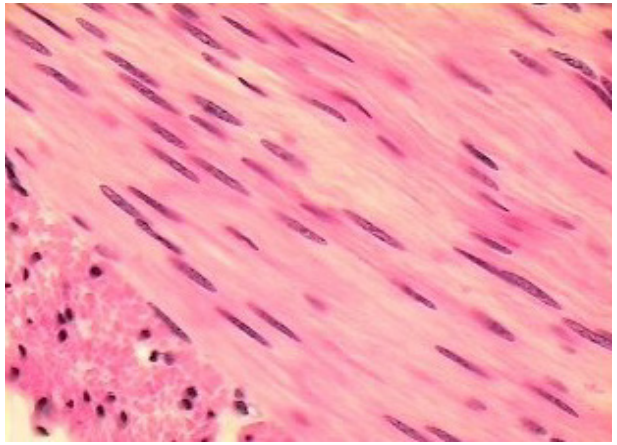

Smooth muscle

Smooth muscle: muscle found in the walls of vessels and organs (also known as visceral muscle); each fiber is an elongated muscle cell, tightly packed together

Look for: (1) lack of prominent wavy appearance as seen in nerves; (2) dark, elongated nuclei that are distinctly intracellular; (3) fibroblasts are rare as smooth muscle synthesizes its own endomysium

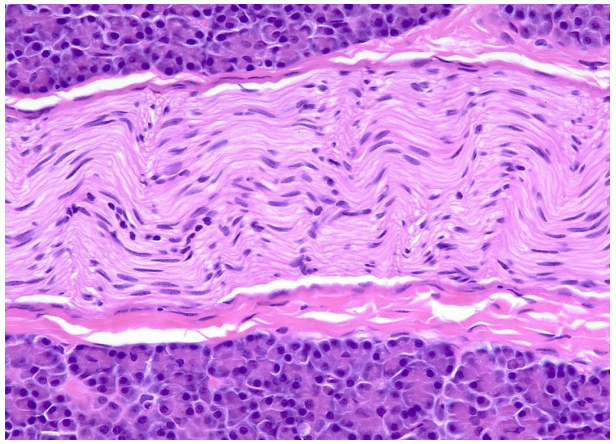

Peripheral nerve

Peripheral nerves: connect the CNS to the rest of the body; consist primarily of axons (cell bodies located elsewhere) surrounded by Schwann cells; layers of CT (endoneurium and perineurium) and associated fibroblasts are also present

Look for: (1) wavy appearance, so nerve may “stretch” with tissue movement; (2) “foamy” pale-staining appearance from high lipid content of myelin; (3) elongated nuclei of Schwann cells situated peripheral to the myelin and flattened nuclei of fibroblasts in the endoneurium CT; (4) surrounded by perinerium CT with fibroblasts; (5) at high magnification, axons and nodes of Ranvier may be visible

Lab 10 – Nervous Tissue

IUSM – 2016

Common Confusion:
Dense CT vs. Peripheral Nerve

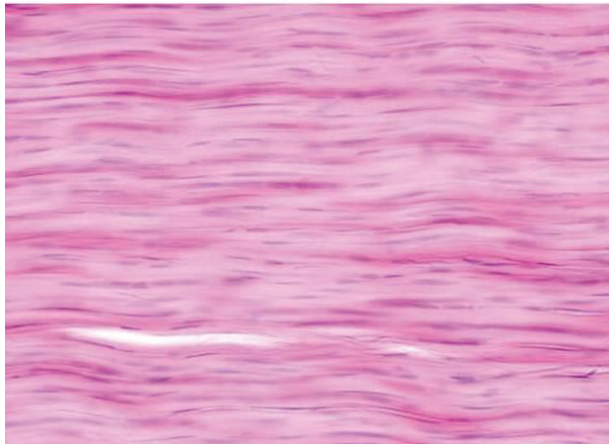

Dense regular CT

Dense regular CT: provides tensile strength to tissue; found in tendons, ligaments, and sometimes in capsules or tissue surrounding other tissue types; composed primarily of large bundles of Type I collagen arranged in a parallel fashion

Look for: (1) small undulations, but tissue generally has a straight appearance; (2) bundles of eosinophilic collagen; (3) flattened nuclei of fibroblasts; (4) separation of tissue (artifact) more commonly seen than in peripheral nerves; (5) lack of a distinctive surrounding/covering tissue

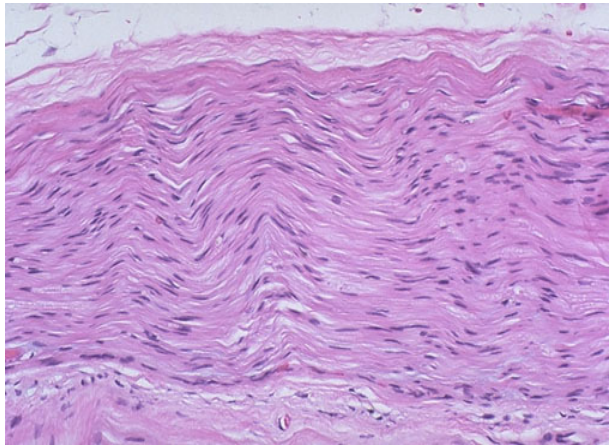

Peripheral nerve

Peripheral nerve: connect the CNS to the rest of the body; consist primarily of axons (cell bodies located elsewhere) surrounded by Schwann cells; layers of CT (endoneurium and perineurium) and associated fibroblasts are also present

Look for: (1) wavy appearance, so nerve may “stretch” with tissue movement; (2) “foamy” pale-staining appearance from high lipid content of myelin; (3) nuclei of both Schwann cells and fibroblasts: elongated nuclei of Schwann cells situated peripheral to the myelin and flattened nuclei of fibroblasts in the endoneurium CT; (4) surrounded by perinerium CT; (5) at high magnification, axons and nodes of Ranvier may be visible

Lab 10 – Nervous Tissue

IUSM – 2016

Common Confusion:
Sensory vs. Autonomic Ganglia

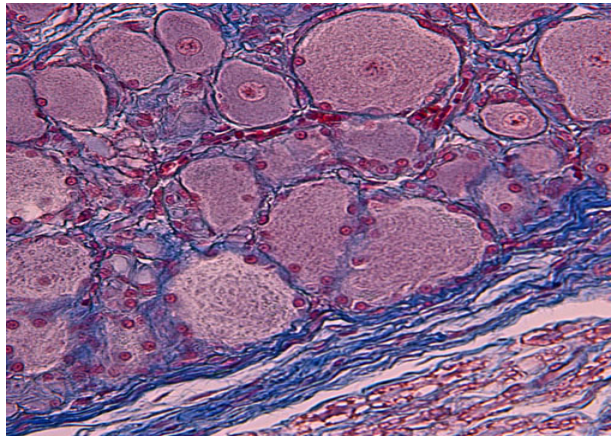

Sensory ganglion

Sensory ganglia: dorsal root ganglia are composed of pseudounipolar neuron cell bodies; they receive sensory information from the peripheral body and transmit it to the CNS

Look for: (1) tightly-packed neurons (unipolar); (2) greater density of rounded satellite cells per neuron than in autonomic ganglia; (3) nuclei are more centrally-located in neurons; (4) neuron cell bodies are larger than in autonomic ganglia (support longer processes); (5) most associated axons are more heavily myelinated

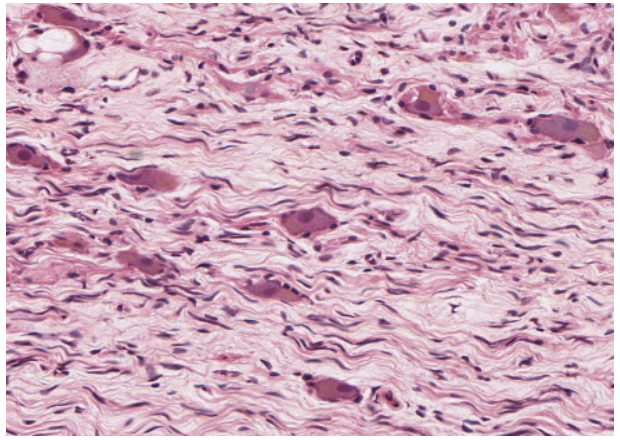

Autonomic (sympathetic) ganglion

Autonomic ganglia: collection of multipolar neuron cell bodies; sympathetic are located near the spinal cord while most parasympathetic are located near or within the organs they innervate; unlike sensory ganglia, autonomic ganglia are "synaptic stations"

Look for: (1) loosely-packed neurons (multipolar) separate by large amounts of dendrites and axons; (2) fewer satellite cells per neuron than in sensory ganglia; Satellite cells tend to be more irregularly placed around neurons due to large number of dendritic processes; (3) neuron nuclei are generally displaced to periphery; (4) lipofuscin; (5) relatively higher number of Schwann cells between neurons; (6) parasympathetic ganglia often composed of only a few neuron cell bodies scattered in supporting tissue

Summary

1. The **central nervous system** (CNS) consists of two major anatomic divisions: the **brain** (**cerebrum** and **cerebellum**) and the **spinal cord**.

2. The CNS is composed of **grey matter** and **white matter**:

   - **Grey matter** contains neuron cell bodies, dendrites, and neuroglia (astrocytes, oligodendrocytes, ependymal cells, and microglia); it forms the outer portion of the brain and the inner portion of the spinal cord; the interneural space lacks connective tissue but is filled with a tightly-packed meshwork of axonal, dendritic, and glial processes and is referred to as **neuropil**.

   - **White matter** is devoid of neuron cell bodies and consists primarily of **myelinated axons** and oligodendrocytes (neuroglial cells); it forms the inner portion of the brain and the outer portion of the spinal cord.

3. Because the central nervous tissue is delicate, it is housed within a protective system of bones, cerebrospinal fluid (CSF), and three layers of specialized CT called **meninges**:

   - **Dura mater** is the outermost meningeal layer; it is tough, thick dense CT.

   - **Arachnoid mater** is the middle meningeal layer; it is more delicate than the dura mater; CSF circulates through the *subarachnoid space* cushioning the brain and spinal cord.

   - **Pia mater** is the innermost meningeal layer; it is delicate CT containing numerous blood vessels and is directly on the surface of the brain and spinal cord.

Summary (cont.)

1. The **peripheral nervous system** (PNS) consists of two major classes of structures: **ganglia** and **peripheral nerves**

2. **Ganglia** are collections of neuron cell bodies, outside of the CNS; there are two primary types:

   - **Sensory (dorsal root) ganglia** are located on the dorsal roots that enter the spinal cord; they contain tightly-packed pseudo-unipolar sensory neurons but lack any synaptic connections.

   - **Autonomic ganglia** contain multipolar motor neurons; they contain synapses of the pre-ganglionic axons onto the ganglionic neurons; they are subcategorized as either *sympathetic* or *parasympathetic* based upon function and location.

3. **Peripheral nerves** contain axons of neurons located either in the CNS or in ganglia; the axons conduct impulses, either motor or sensory, to or from the CNS; the axons are supported by *Schwann cells*, which may also myelinate them, and are organized into *fascicles* in an arrangement of CT layers similar to that of skeletal muscle:

   - **Epineurium** is the outermost layer surrounding the nerve; it is dense CT.

   - **Perineurium** is the middle layer; it surrounds fascicles of the nerve and contributes to establishment of the *blood-nerve barrier*.

   - **Endoneurium** is the innermost layer; it surrounds individual axons and Schwann cells.

Lab 10 – Nervous Tissue

IUSM – 2016

Neuroglial Cells of the Central and Peripheral Nervous Systems

Cell	Location (CNS/PNS)	Function	Characteristic Appearance
Astrocyte			
Schwann cell			
Oligodendrocyte			
Ependymal cell			
Microglia			
Satellite cell			